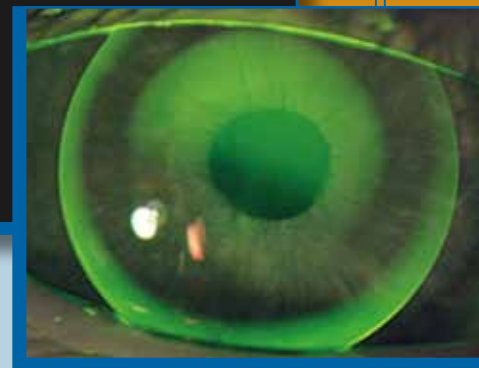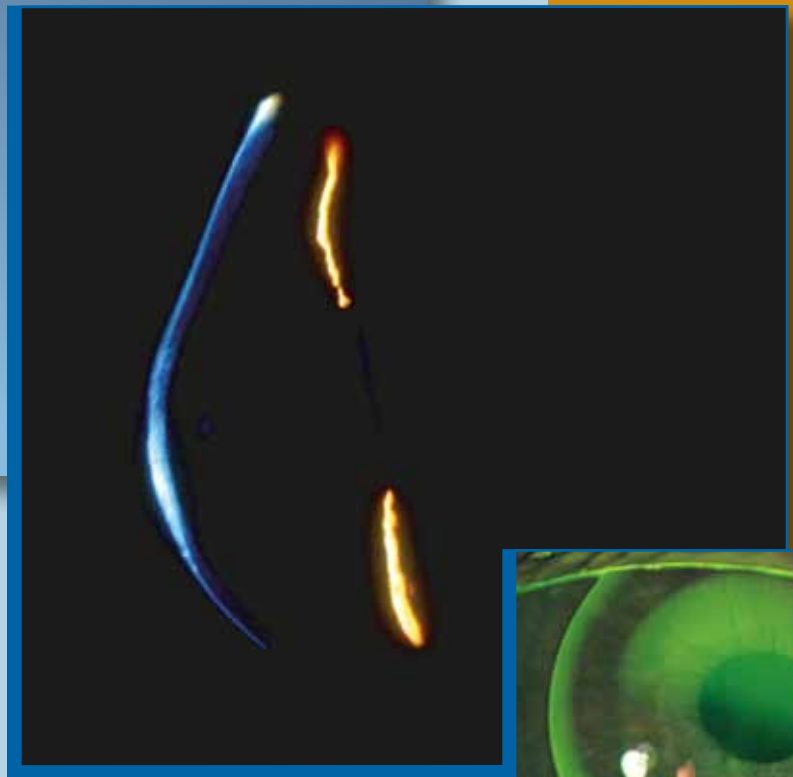


Correction of Keratoconus with GP Lenses



Centre for Contact Lens Research
School of Optometry
University of Waterloo, Canada

Introduction

About This Book

Keratoconus can be safely and effectively corrected with the use of gas permeable (GP) contact lenses. The detection of the various types of keratoconus has been simplified with the use of corneal topographers and optical coherence tomographers. The management of this condition has also been made easier with the use of those tools to more accurately match lens type with cone type. The advances in manufacturing and lens design have given the practitioner a larger variety of lenses from which to choose. This booklet hopes to aid the practitioner in choosing an appropriate lens design based on standard curvature and novel corneal metrics that can be used to determine the needs of keratoconus patients. With this booklet, we hope to demonstrate the ease of fitting and managing keratoconus.

Centre for Contact Lens Research

Established in 1988, the Centre for Contact Lens Research at the School of Optometry, University of Waterloo in Canada focuses its research on the effects of contact lens wear on the eye. Composed of faculty, researchers, graduate students and administrative and technical staff, clinical trials and basic research performed at the CCLR are the result of collaboration with contact lens and related industries. Many of our activities are also directed at supporting the development of optometric education for practitioners. Please visit <http://cclr.uwaterloo.ca> for more information about our work.

Acknowledgements

EXECUTIVE EDITOR

Desmond Fonn, MOptom, FAAO
Director, Centre for Contact Lens Research
Professor, School of Optometry
University of Waterloo

PROJECT MANAGER

Bonnie Boshart, BBA
Business Development Coordinator
Centre for Contact Lens Research

AUTHOR

Luigina Sorbara, OD, MSc, FAAO
Clinical Scientist, Centre for Contact Lens Research
Associate Professor, School of Optometry
University of Waterloo

EDITORS

Craig Woods, PhD, FAAO
Research Manager, Centre for Contact Lens Research
Adjunct Associate Professor, School of Optometry
University of Waterloo

Alisa Sivak, MA
Communications Coordinator
Centre for Contact Lens Research

CONTRIBUTORS

Katrin Müller
Aalen diploma student, School of Optometry
University of Waterloo

Kristine Dalton
Contact Lens Resident and MSc student
School of Optometry, University of Waterloo

Jalaiah Varikooty
Clinical Scientist, Centre for Contact Lens Research
University of Waterloo

Jyotsna Maram
PhD student, School of Optometry
University of Waterloo

Adam Keech
MSc student, School of Optometry
University of Waterloo

We would like to acknowledge and thank the International Association of Contact Lens Educators (IACLE) for the images by Dr. David Miller (Figures 1, 11 and 65) and Hilmar Bussacker (Figure 29).

REVIEWERS

Hans Bleshøy, BSc, PhD, MCOptom, FAAO
Danish Contact Lens Consultants
Skive, Denmark

Timothy B. Edrington, OD, MS
Professor, Southern California College of Optometry
Fullerton, CA, USA

Sergi Herrero
Diploma in Optics and Optometry
Barcelona, Spain

Craig W. Norman, FCLSA
South Bend Clinic
South Bend, Indiana, USA

Philippe Seira, Dipl. Augenoptiker
Lecturer at the University of Applied Sciences
Northwestern Switzerland
Olten, Switzerland

José L. Garrido Tundidor
Master of Optometry and Vision Sciences
Diploma in Optics and Optometry
Barcelona, Spain

Richard Wu BSc, OD, PhD, FIOS, FIACLE
Taipai Professional Optometry Center
Taiwan

Osbert Chan, PhD
Hong Kong

DESIGN

Christina Englund
Senior Graphic Designer, Boston Products Group
Bausch & Lomb Incorporated

Contents

- 1. Introduction to Keratoconus**1
 - Epidemiology of keratoconus 1
 - Associated conditions 1
 - Methods of correction of keratoconus 1
 - Contact lenses 1
 - Spectacle lenses 2

- 2. Classification of Keratoconus**3
 - Corneal topography 3
 - Types of keratoconus 4
 - Advancement of the disease (corneal thickness) 4

- 3. Diagnosis and Signs**6
 - History and symptoms 6
 - Slit lamp biomicroscopy 6
 - Ophthalmoscopy and retinoscopy 7
 - Topography, keratometry and pachymetry 7
 - Refraction and vision 8
 - Differential diagnosis 8

- 4. Methods of Correction with Contact Lenses**9
 - Corneal gas permeable (GP) contact lenses 9
 - Corneal-scleral and semi-scleral GP contact lenses 10
 - Mini-scleral and scleral GP contact lenses 11
 - Piggyback designs 11
 - Soft contact lenses 12

- 5. Lens Designs**13
 - Corneal contact lenses 13
 - Spherical multicurve lenses 13
 - Spherical center and spherical periphery 13
 - Spherical center and aspheric periphery 14
 - Aspheric contact lenses 14
 - Semi- and mini-scleral contact lenses 14
 - Piggyback lenses 14

- 6. Lens Fitting**15
 - Choosing the correct lens design 15
 - General considerations 15
 - BOZR selection 15
 - Power considerations 17

Fitting procedures: selection of appropriate BOZD and TD	18
Fitting small diameter lenses (8.5 to 9.3mm)	18
Fitting medium diameter lenses (9.4 to 9.9mm)	19
Fitting large TD corneal (10.0 to 12.8mm) and corneal-sclerals (12.9 to 13.5mm)	19
Fitting semi-scleral lenses (13.6 to 14.9mm TD) and mini-sclerals (15.0 to 18.0mm TD)	20
Peripheral lens design	22
Determining axial edge lift (AEL)	22
Toric or unequal peripheries	23
Evaluation of appropriate fit	24
Fluorescein pattern	24
3-point touch (divided support)	24
Apical touch	24
Apical clearance	25
Ideal axial edge clearance	25
Minimum edge clearance	25
Excessive edge clearance	26
Lens centration and movement	26
Over-refraction	26
Fluorescein simulations from topography maps	26
7. Follow-up and Management Strategies	27
Follow-up procedures and visits	27
Complications necessitating lens changes	28
Altering lens design	29
Changing BOZR	29
Changing BOZD	29
Changing TD	29
Changing AEL	29
Changing sectoral AEL	29
Changing center thickness	30
Changing lens power	30
Refitting with different lens and/or design	30
Spherical to aspheric BOZD	30
Spherical to aspheric lens periphery	30
Fixed to floating BOZD	30
Corneal lenses to semi-scleral design	31
8. Complications	32
Corneal staining	32
Solution toxicity staining	32
Three and nine o'clock staining	32
Patch or linear staining due to an abrasion or foreign body	32

Apical staining	33
Dimple veiling	33
Vision	33
Lens decentration	34
Corneal indentation	34
9. Reference List	35
Appendix A: Etiology and Genetics	40
Appendix B: Surgical Correction of Keratoconus	42
Penetrating keratoplasty (full thickness)	42
Lamellar keratoplasty (partial thickness)	42
Deep lamellar keratoplasty	42
Disparate thickness lamellar keratoplasty	42
Intra-lamellar keratoplasty	42
INTACS®	43
Cross-linking agents	43
Appendix C: Detection of Keratoconus with the Use of the Orbscan II	44
Appendix D: Fitting Semi- and Mini-Scleral Lenses	45
Central sagittal depth fitting	45
Mid-peripheral or limbal zone fitting	45
Scleral fitting zone	46
Appendix E: Fitting Examples	47
Fitting example: centered or nipple cone (early stage)	47
Fitting example: oval cone (severe stage)	51
Appendix F: Keratometer Readings Conversion Chart	55
Appendix G: Conversion Chart: Distance Vision Nomenclature	56

1. Introduction to Keratoconus

Epidemiology of keratoconus

Keratoconus is a progressive, typically asymmetric, non-inflammatory axial ectasia of the cornea (Figure 1). It is bilateral in 96% of cases, developing asymmetrically, typically with the diagnosis of the disease in the second eye lagging about five years behind that of the first. The course of the disease is highly variable, classically beginning from puberty to the mid-thirties and progressing for 10–15 years until the fourth or fifth decade of life. The onset of keratoconus is usually followed by a period of relative stability or very slow progression, which may be interspersed with episodes of more rapid progression. The end point for progression is also variable: The severity of the disorder at the time it stabilizes can range from mild, irregular astigmatism correctable with spectacles or contact lenses, to severe thinning, protrusion and scarring that may require keratoplasty or other surgical methods of treatment.

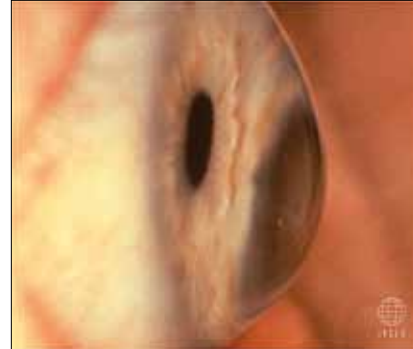


Figure 1. Profile view of keratoconic cornea

The patient begins with a cornea that is either spherical or that has regular astigmatism. Progression is initially characterized by central corneal stromal thinning, apical protrusion resulting in the steepening of the corneal curvature, and variable degrees of scarring. The thinner apex becomes downwardly displaced, giving rise to irregular astigmatism, a hallmark of the disorder, which results in mild to marked impairment in the quality of vision.

The incidence of keratoconus varies from 50 to 230 per 100,000 in the general population; that is, approximately 1 in 2000 people. The prevalence of keratoconus has been reported to be as high as 0.6% and as low as 0.05% of the general population. Appendix A reviews the etiology and genetics of keratoconus.

Associated conditions

Keratoconus is most commonly an isolated condition, despite multiple reports that it appears alongside other disorders, including Down syndrome¹, Ehlers-Danlos syndrome, osteogenesis imperfecta, mitral valve prolapse and patients with atopic diseases. It may also develop from forms of ocular trauma such as contact lens wear or eye rubbing.

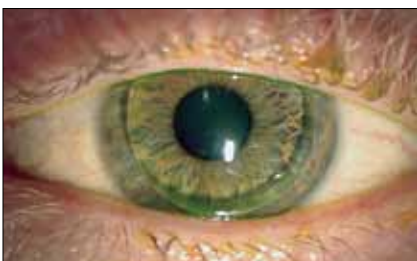

Figure 2. White light contact lens on KC

Methods of correction of keratoconus

Contact lenses

Contact lenses eventually become necessary in nearly all cases of keratoconus, to provide optimal vision (Figure 2), and approximately 10% to 26% of patients eventually need corneal surgery. It is possible that the use of contact lenses in the keratoconic eye may lead to corneal

¹ Trisomy 21 increases the incidence of keratoconus from 50- to 300-fold.

scarring; however, reasonable evidence indicates that the cornea may scar with or without contact lens wear. Prognosis of this condition is unpredictable and its progression is variable; annual or more frequent eye examinations are indicated. The disease does not cause blindness, but may compromise quality of life, although keratoconic patients can usually still drive and read throughout most of the progression of the condition.

Most keratoconic patients (74% of eyes) can be non-surgically treated, while the remaining (26%) are managed with keratoplasty.

Crews et al. (1994) found that the majority (53%) of keratoconic patients were best corrected with contact lenses and the remaining 21% (mild keratoconus) with spectacles or no correction at all in at least one eye.

Spectacle lenses

As keratoconus progresses, the amount of corneal irregular astigmatism increases due to the distortion caused by the distension of the cornea as it becomes ectatic. This irregular astigmatism is non-orthogonal (that is, having multiple foci), making it difficult to achieve an adequate refraction, both objectively and subjectively. The spectacle prescription is therefore less effective and does not provide suitable optical results, particularly in the later stages of the disease.

Further, although keratoconus is a bilateral condition, one eye tends to lead while the other eye lags behind in its progression; the anisometropia or antimetropia that this causes results in spectacle magnification intolerances.

Since it becomes increasingly difficult to prescribe spectacles as the condition worsens, reliance on contact lenses becomes essential. On the other hand, a pair of spectacles should be prescribed, so that they can be worn on days when contact lenses cannot be tolerated. Reading spectacles, to be worn over contact lenses, should also be prescribed for presbyopes.

Surgical correction of keratoconus is discussed in Appendix B.

2. Classification of Keratoconus

Corneal topography

One of the most important tools in detecting and managing keratoconus is videokeratography (VKE). A common deficiency in the ability to detect keratoconus has been the use of an axial (sagittal), rather than instantaneous (tangential or local) radius of curvature. Sagittal scales look specifically at the visual optics of the cornea, while tangential scales assess the physical shape of the cornea. The use of axial radius in videokeratography distorts the apparent position and power of an apex that is located in the peripheral cornea since it is referenced to the VKE axis. Figures 3a and 3b illustrate the difference in view between axial and tangential maps.

Axial (sagittal) map	Tangential (instantaneous) map
Shows the area of optical impact on vision, but not the actual size and shape of the cone.	Shows where the cone is localized, matching the shape seen clinically.
Averages the corneal power, underestimating the steeper powers and overestimating the flatter periphery.	Recalculates the corneal radii without reference to the VKE axis, making steeper areas appear steeper and flatter areas appear flatter.

This distortion is even more exaggerated in keratoconus, where steeper regions outside of the map center are underestimated in radius, and flatter regions in the periphery are overestimated. Use of the tangential map aids in a more accurate representation of the position and size of the cone due to the recalculation of the axial readings, now referenced to each adjacent ring rather than the VKE axis. The use of elevation maps distinctly

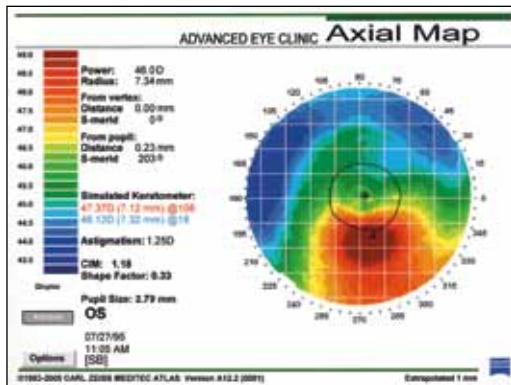


Figure 3a. Axial curvature map

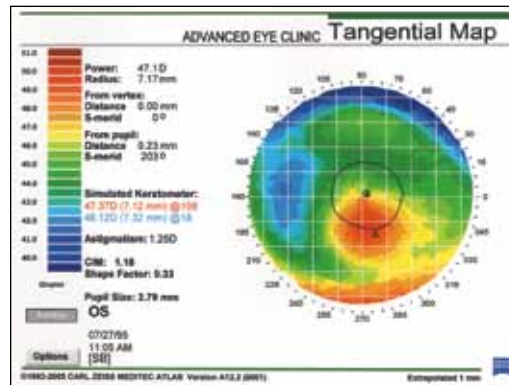


Figure 3b. Tangential curvature map

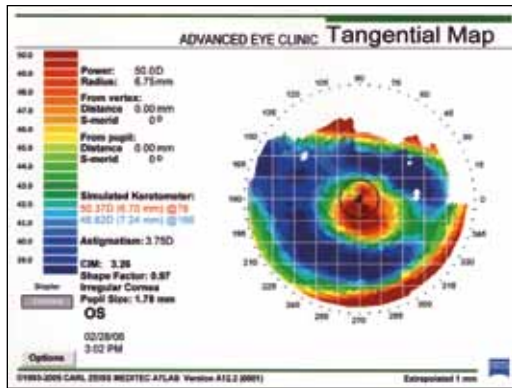


Figure 4a. Centered cone, topography map

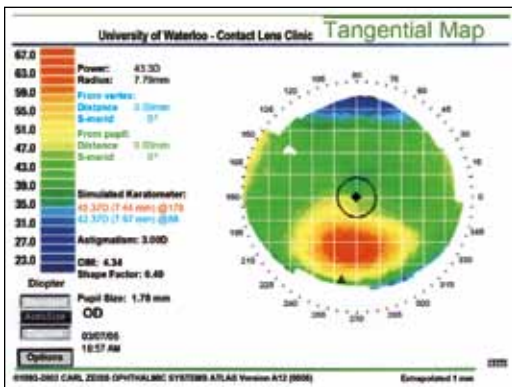


Figure 5b. Oval cone, topography map

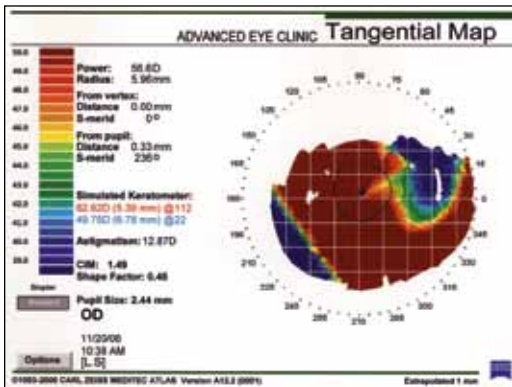


Figure 6c. Globus cone, topography map

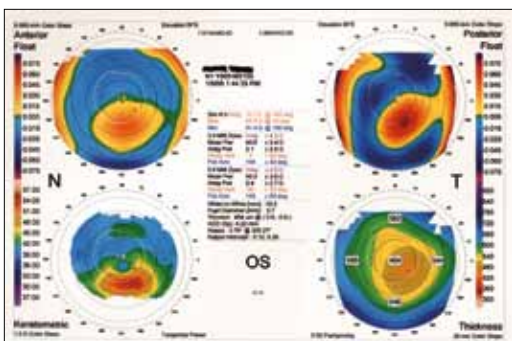


Figure 7a. Pellucid marginal degeneration (PMD), topography map (note against-the-rule astigmatism)

indicates the presence and positioning of the cone, but without radius of curvature, it is not as useful for contact lens fitting.

The use of the Orbscan II topographer, which measures both elevation and radius of curvature, for the detection and management of keratoconus is discussed in Appendix C.

Types of keratoconus

Corneal topography can help to identify the severity and the type or shape of the keratoconic cone. Classification of keratoconus can be based on the severity of the corneal cone curvature, i.e. the central averaged simulated keratometric readings provided by the corneal topographer. A common estimation of severity is as follows: If this average is less than 50.00D (6.75mm) the cone is considered to be in its early stage; if it is 50.00 to 56.00D (6.75 to 6.03mm), the cone is advanced, and beyond 56.00D (6.03mm) the cone is considered to be severe.

Secondly, the location or shape of the cone commonly identified, e.g. nipple or central type, oval, inferior-temporal or nasal type, and globus or generalized type (Figures 4a, 5b and 6c). Another condition or variation of keratoconus is pellucid marginal degeneration (PMD), in which the thinning and cone occur inferiorly nearer the limbus (Figure 7a) than with oval-type keratoconus, thereby inducing against-the-rule astigmatism, a hallmark in the diagnosis of this variant. Often this is demonstrated as a “butterfly” or “kissing dove” map.

Advancement of the disease (corneal thickness)

As keratoconus progresses, central corneal thinning occurs, mainly in the stroma and very often the epithelium, creating a conical corneal shape. Methods of pachymetry measure of topographic corneal thickness include:

- slit scanning techniques, such as the Orbscan II (Bausch & Lomb, NY), Figure 8a
- rotating Scheimpflug photography, such as the Pentacam (Oculus, Germany), Figure 8b
- optical coherence tomography, such as the Visante OCT (Zeiss Meditec, CA), Figure 8c

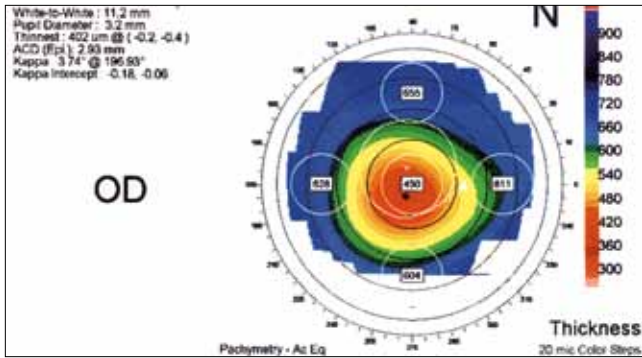


Figure 8a. Pachymetry map using Orbscan II

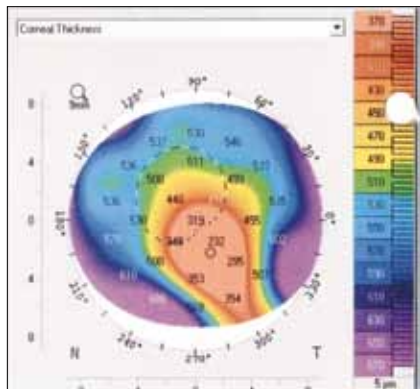


Figure 8b. Pachymetry map using Pentacam

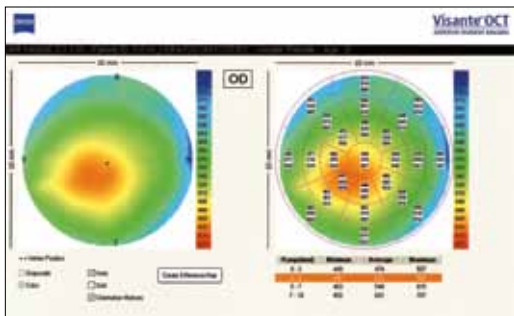


Figure 8c. Pachymetry map using Visante OCT

- ultrasound pachymetry, such as the Artemis instrument (UltraLink, LLC), Figure 8d

These relatively new devices offer topographic views of the cornea, so that its thickness can be identified at any point along any meridian, including the thinnest point.

The measurement of topographic thickness allows for careful monitoring of the progression of the condition, since the same points and locations can be measured over time. Newer high-definition spectral domain OCTs can enhance the resolution of these images so that epithelial and total corneal thickness can be measured more precisely. Although there is no specific means of classifying the severity of keratoconus based on corneal thickness, there are significant differences between the normal and keratoconic eyes with respect to thickness (all types and levels of severity pooled together).

It is generally accepted that corneal thicknesses approaching less than 300µm, should be considered for referral to a corneal surgeon for an assessment.

Studies using newer technology such as the OCT indicate a difference in corneal thickness between the normal and keratoconic eye, ranging from 89 to 109µm. Although patients with keratoconus can have corneal thickness at the cone apex in the normal range, in one study the average minimum center thicknesses are $540 \pm 30\mu\text{m}$ for the normal eye and $443 \pm 64\mu\text{m}$ for the keratoconic eye.

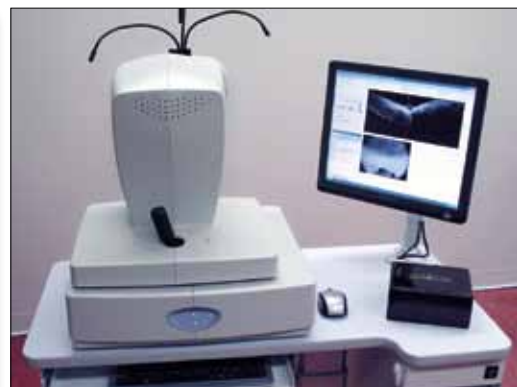

Figure 8d. Spectral domain OCT

3. Diagnosis and Signs

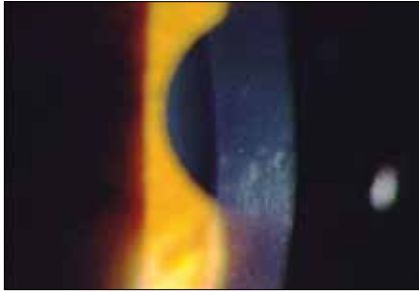


Figure 9. Vogt's striae

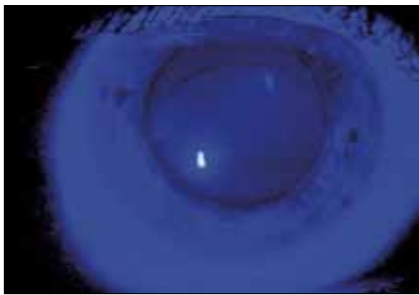


Figure 10. Fleischer's ring

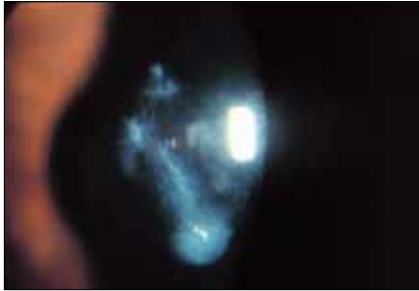

Figure 11. Corneal scarring

History and symptoms

An initial diagnosis of keratoconus may be made during a patient's youth or up to their mid-thirties. Symptoms include lack of crisp or sharp vision, particularly under low illumination (e.g., while driving or watching TV in a dark room).

The following is a list of symptoms and signs that are associated in the diagnosis of keratoconus:

- Mild or marked reduction of spectacle-corrected high- and low-contrast visual acuity at both distance and near
- Change in vision occurring from puberty onwards (i.e. up to a patient's mid-thirties or forties, but late onset is also possible)
- Monocular diplopia and image ghosting
- Abnormal contrast sensitivity
- Ocular irritation and dry eye symptoms
- History of eye rubbing
- History of atopic disease
- History of systemic condition that may be associated with keratoconus

Slit lamp biomicroscopy

The following is a list of biomicroscopic signs identifying the condition:

- Prominent corneal nerves
- Vogt's striae, stress lines in posterior stroma or at Descemet's, which disappear transiently on digital pressure (Figure 9)
- Fleischer's ring (iron ring) occurring at the junction of the thinning corneal sector and the thicker, unaffected area (Figure 10)
- Apical epithelial or subepithelial corneal scarring (Figure 11)
- Munson's sign, inferior displacement of the lower lid on down gaze (Figure 12)
- Corneal hydrops (late stages), a breakdown in endothelial function causing acute epithelial corneal edema followed by scarring (Figure 13)

Ophthalmoscopy and retinoscopy

These signs can occur early in the progression of the condition and aid in early diagnosis:

- Visualization of the cone in the red reflex within the pupil area (Charleaux's oil droplet sign)
- Irregular or scissoring of the retinoscopic reflex
- Change in cylinder axis of astigmatic correction initially, followed by change in cylinder amount
- Myopia and irregular astigmatism (usually with-the-rule or oblique) for keratoconus
- Tendency towards hyperopia and against-the-rule irregular astigmatism with PMD

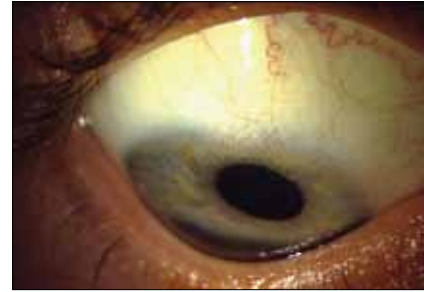

Figure 12. Munson's sign

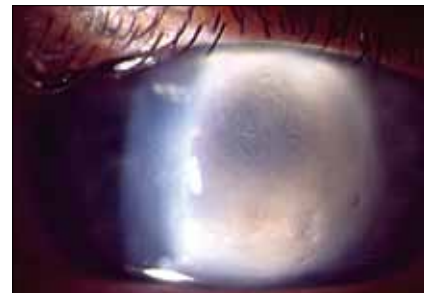

Figure 13. Corneal hydrops

Topography, keratometry and pachymetry

Defining cone type and size using the videokeratoscope (VKE)

The **nipple** or **centered** cone is a small paracentral anomaly, typically less than 5mm in diameter. As this type of cone advances, the cone becomes steeper and smaller as can be seen on the VKE maps in Figures 14a and 14b.

In the oval (horizontal meridian) cone, the apical center is displaced from the visual axis into the inferior and usually temporal quadrant, with an average of 5–6mm diameter. As the cone progresses it becomes

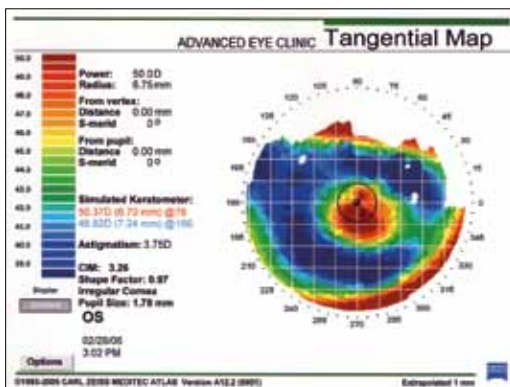


Figure 14a. Early centered cone, topography map

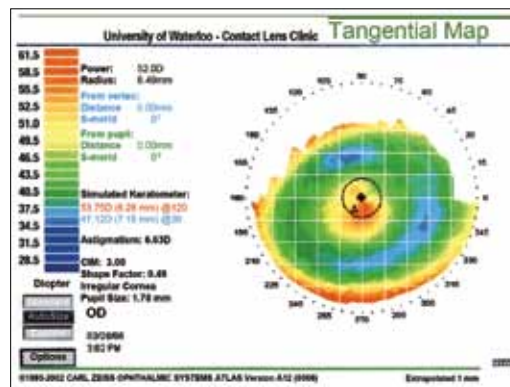


Figure 14b. Late centered cone, topography map

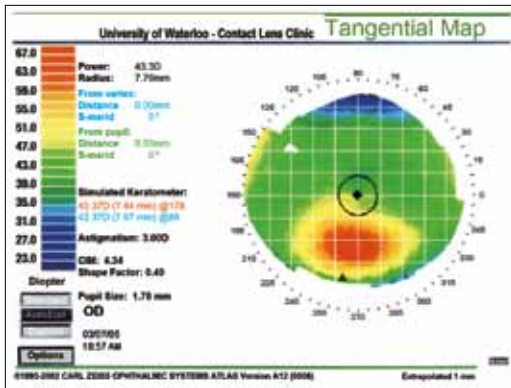


Figure 15a. Early oval cone, topography map

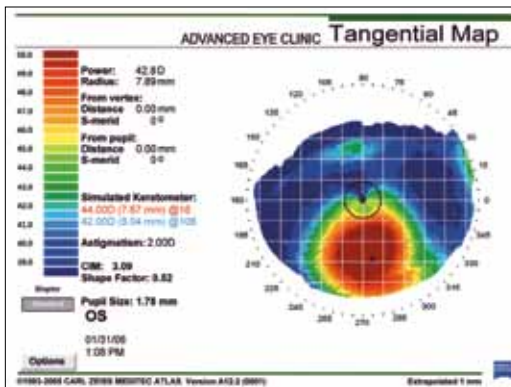


Figure 15b. Moderate oval cone, topography map

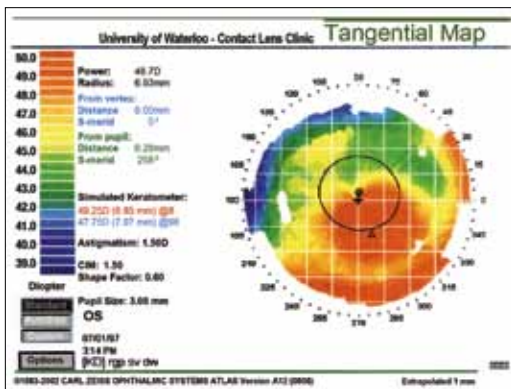


Figure 15c. Severe oval cone, topography map

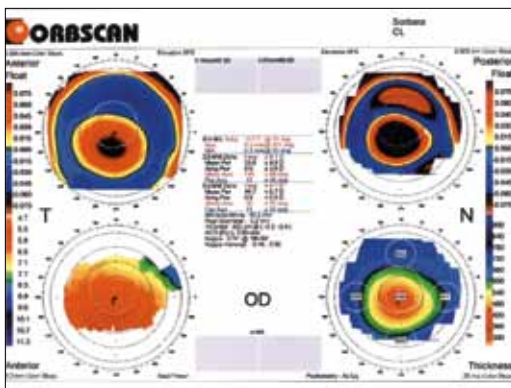


Figure 16. Globus cone, topography map

more displaced from the central position and larger in diameter as it steepens in radius (Figures 15a, 15b and 15c).

The globus cone is the largest of the three types, often involving nearly three-quarters of the corneal surface (Figure 16).

Progression of corneal steepening

As the centered or nipple cone progresses, it thins apically and centrally inducing more irregular keratometric mires and non-orthogonal with-the-rule or oblique astigmatism. As the oval cone progresses, it thins paracentrally and the apex of the cornea tends to sag inferiorly and temporally, inducing irregular keratometric mires, asymmetry of the topographic pattern and also non-orthogonal with-the-rule or oblique astigmatism. Both variations have interocular asymmetry (Figures 15a, 15b and 15c). In cases of PMD, the cone thins inferiorly and sags close to the inferior limbus inducing non-orthogonal against-the-rule astigmatism (Figure 7a).

Refraction and vision

Myopia and astigmatism increase with the progression of both centered and oval cones, from $-1.00D$ to more than $-10.00D$ (sphere and cylinder power), with a decreasing ability to achieve acceptable spectacle acuity. Similarly, an increase in against-the-rule astigmatism up to $20.00D$ have been reported occurs with PMD due to excessive inferior steepening. The patient becomes more hyperopic, due to the excessive corneal flattening over the pupil area. Also, acceptable spectacle high- and low-contrast acuities diminish with its progression, typically ranging from 20/25 to 20/80 or worse. See Appendix G for Conversion Chart: Distance Acuity Nomenclature.

Differential diagnosis

It may be important to differentiate the type of cone and condition (i.e. is it central or oval keratoconus or is it PMD) in order to properly counsel the patient regarding prognosis of the condition and which surgical and non-surgical therapies apply. In contact lens fitting it is essential that the type and the size of the cone are identified, so that the lens can be fit (including lens parameters and design) more efficient.

4. Methods of Correction with Contact Lenses

Corneal gas permeable (GP) contact lenses

Lenses with diameters (TD) between 8.0mm and 12.8mm are considered corneal lenses. As the diameter of the cone increases, so too should the back optic zone diameter (BOZD), the base curve radius and the lens diameter, resulting in a better match between the sag of the cone and the sag of the back optic zone, as indicated by the arrows on the lenses and the topographic maps. Seeking a match between these variables is accomplished with the use of a corneal topographer, with which gridlines may be used to measure the size, position and area of the cone. Communication with your lab is important for the proper fitting of these lenses, including knowing the diameter of the back optic zone and an understanding as to whether the optic zone diameter changes with the back optic zone radius of the contact lens (floating BOZD) or remains constant (fixed BOZD), changing only when the lens diameter changes (Figures 17 to 25). See page 13, Tables 1 and 2.

If the optic zone is too large compared to the cone diameter, the sag of the contact lens is greater than the cone and clearance around the cone will lead to the formation of bubbles in the pre-lens tear film, due to the large gap of clearance around the cone. These conditions may affect visual performance. If the optic zone of the lens is too small, the sag of the contact lens will be smaller than the sag of the

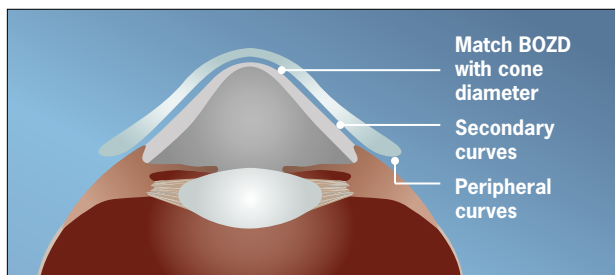


Figure 21. Illustration of matching BOZD with cone diameter

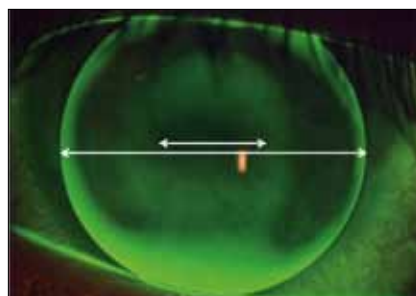


Figure 17. Centered cone (floating BOZD)

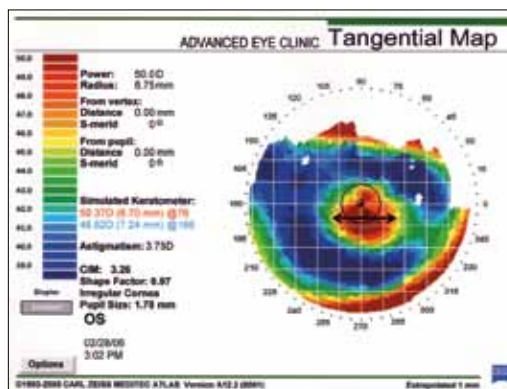


Figure 18. Topography of centered cone

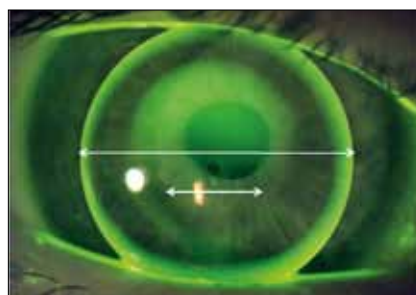


Figure 19. Early oval cone (fixed BOZD)

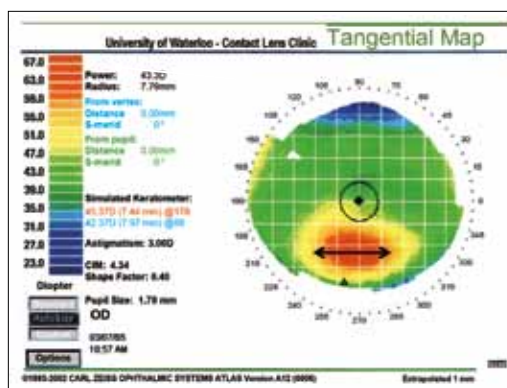


Figure 20. Early oval cone

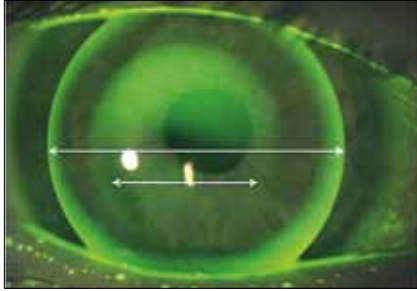


Figure 22. Moderate oval cone (fixed BOZD)

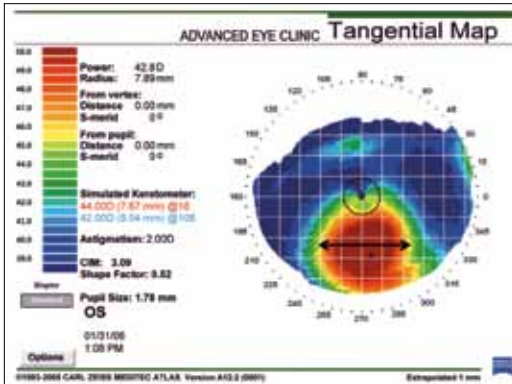


Figure 23. Topography of moderate oval cone

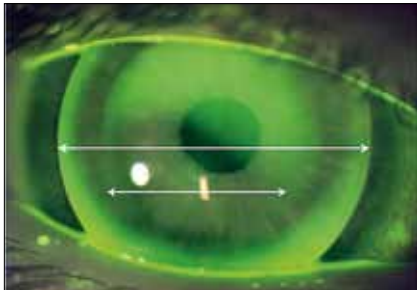


Figure 24. Severe oval cone (fixed BOZD)

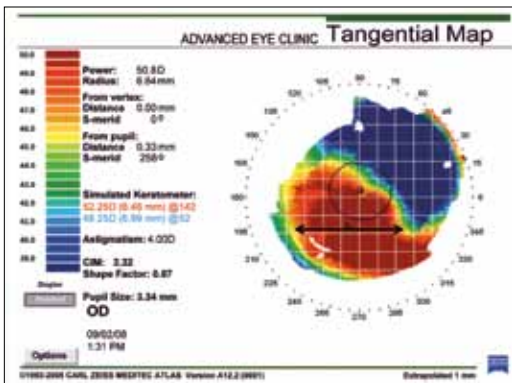


Figure 25. Topography of severe oval cone

cone, bearing the lens on the cone and resulting in a lens that is unstable and decentered on the cornea (Figure 21). Once the BOZD and TD have been calculated, a common lens design is to ensure that the back optic zone radius (BOZR) results in a gentle three-point-touch or divided support over the cone (Figures 17 to 25). See tables on page 13.

The peripheral zone of the lens needs to flatten more than the peripheral cornea and in doing so, will have to have an axial edge lift that is much higher than that of a lens designed for the average eye with an average eccentricity value (0.5 to 0.6). Eccentricity values for keratoconic eyes range from 0.65 to greater than 1.0 in advanced cases.

Corneal-scleral and semi-scleral GP contact lenses

With the introduction of hyper-Dk GP lens materials, practitioners have become more reassured in prescribing larger diameter lenses. Lens diameters between 12.9mm and 13.5mm can be regarded as corneal-scleral lenses and from 13.6mm to 14.9mm can be regarded as semi-scleral lenses.

Three portions of the lens need to be considered in fitting and may be adjusted independently:

- the corneal portion (BOZD/BOZR),
- the mid-peripheral portion over the corneal-scleral (c-s) junction
- the scleral-conjunctival (s-c) portion

The corneal-scleral lenses are fit with slight apical clearance or alignment centrally, clearance over the corneal-scleral junction and alignment in the scleral-corneal zone. Semi-scleral lenses

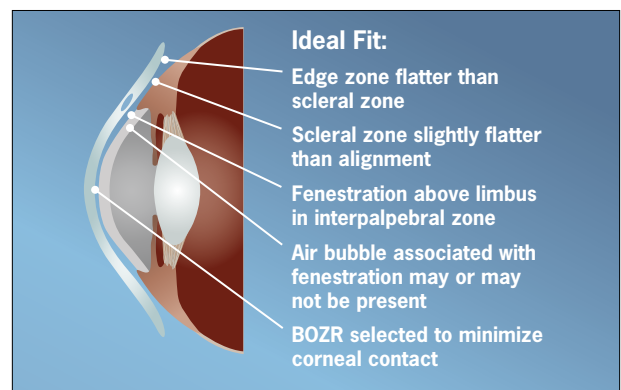


Figure 26. Illustration of scleral design

are fit similarly, but more apical clearance is necessary to induce tear pumping under the lens.

Corneal topographical maps reveal very large and distorted cones (keratoglobus) that may be inferiorly displaced (PMD) or irregularly-shaped (oblate, as with PKP), all of which would benefit from the very large BOZDs that these lenses provide.

Mini-scleral and scleral GP contact lenses

Lens diameters between 15.0mm and 18.0mm could be considered mini-scleral, and from 18.1mm to over 24mm are referred to as scleral lenses. Fitting these lenses requires an understanding of the shape of the corneal-scleral junction and scleral topography.

Fitting these lenses without the use of impression molding techniques is challenging, but the recent introduction of trial sets and optical coherence tomography as means of visualizing the anterior segment of the eye has aided in the design and fitting of these lenses. These lenses are designed to align and rest on the scleral conjunctiva and to vault over the cornea, without touching the cone (Figure 26). The lens sag must be greater than the corneal sag in order to achieve this type of fitting relationship. In trapping tears beneath the lens, these scleral lenses may have a therapeutic advantage for the dry eye (e.g. Graft versus Host disease or Sjögren's syndrome) in addition to masking very large areas of corneal irregularity.

These lenses offer advantages for advanced cases of PMD, advanced keratoglobus and for proud or tilted PKP grafts (or any other post-refractive surgery distortion), providing comfort and better optics. Similar to the semi-scleral designs each of the three zones of the lens must be considered individually for successful fitting of these designs. Tear exchange is accomplished through a pumping action of the upper eyelid over the contact lens surface, inducing flexure (positive pressure) of the center of the lens and negative pressure as the lens periphery draws tears under the lens (Figures 27 to 28).

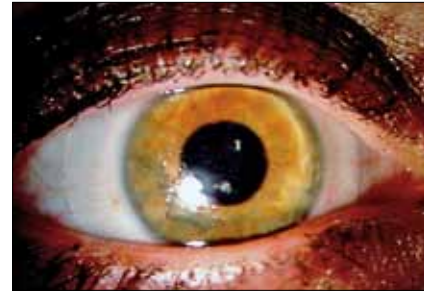


Figure 27. Scleral lens, white light

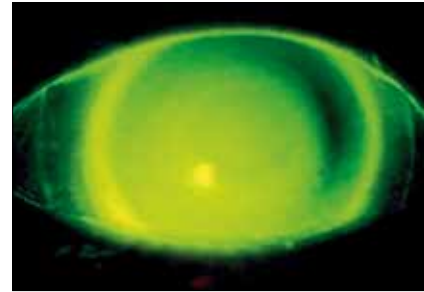


Figure 28. Scleral lens, fluorescein pattern

Lens Diameter	Classification
8.0–12.8mm	Corneal lens
12.9–13.5mm	Corneal-scleral
13.6–14.9mm	Semi-scleral
15.0–18.0mm	Mini-scleral
18.1–24.0mm	Scleral

Piggyback designs

The traditional piggyback system, in which a countersink (ranging from 8.0 to 9.8mm) was carved out of the hydrogel carrier lens, for example, the UltraVision KeraSoft® lens, (ranging from 12.5 to 14.5mm) and the rigid lens sat within in it, had the advantages of centering the contact lens over the pupil in mild to moderate cases of oval cones and improved comfort but has the disadvantage of reducing the oxygen tension beneath the two

lenses to very low levels (Figures 29 to 30b). With the advent of silicone hydrogels, there has been a revival of interest in piggybacking, with off-label use of these lenses (only CIBA Night and Day™, Bausch & Lomb

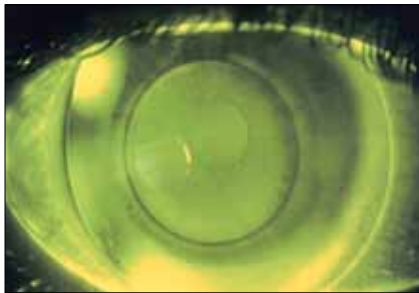


Figure 29. Piggyback, high molecular weight fluorescein

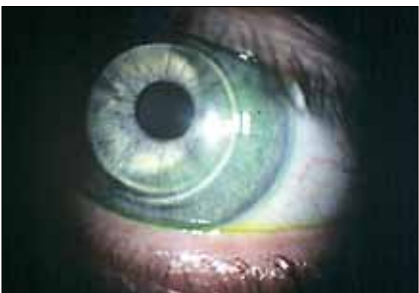

Figure 30a. Piggyback, white light




Figure 30b. Illustration of piggyback

PureVision® and Vistakon Oasys™ lenses have therapeutic labeling).

This combination adds increased oxygen tension beneath the two-lens system, from 34mm Hg (PMMA and low water lens) to 95mm Hg (GP and SCL), which translates to a Dk/t of 39×10^{-9} (cm/sec)(ml O₂ x mm Hg): well above the range needed to avoid corneal edema (24×10^{-9} [cm/sec][ml O₂ x mm Hg]) for daily wear.

Other advantages of the piggyback system with silicone hydrogels in addition to improved comfort are: reshaping the corneal contour slightly and corneal protection when chronic abrasions are present and improved over hydrogels. Centration can only be offered by having plus power in the soft lens, since there is no countersink. The plus power (+0.50D) aids in lens centration by tightening the central fit of the GP lens over it, bringing the lens to the center of the soft lens. Due to the tightening/steepening effect, the periphery of the GP lens may need to be reordered with increased axial edge lift, to avoid a sealing effect on the soft lens.

Soft contact lenses

The role of soft lenses in correcting an irregular cornea with irregular astigmatism is limited. Consider using these lenses when all else fails and the patient is intolerant of GP lens wear (more and more uncommon with the increasing use of large diameter GP lenses with semi- and mini-scleral designs, which rest outside the limbus). Spherical soft lenses with very thick center thicknesses (0.3 to 0.5mm) may mask some irregularity, but consider their low oxygen permeability and low success rate. Alternatively, consider using back surface toric lenses (also with thick center thicknesses due to prism stabilization) that can be customized to up to 11.00D cylinder correction. In general, an astigmatic spectacle overcorrection is needed to balance the poor optical results. Another option that may become available is the use of custom wavefront soft lenses that could correct some higher order aberrations provided that rotation and translation of the lens could be controlled.

5. Lens Designs

Corneal contact lenses

Spherical multicurve lenses

Spherical center and spherical periphery: The Soper bicurve lens design was the early PMMA lens used for keratoconus. It had a small diameter and a fixed back optic zone, with a steep central base curve and a flat secondary curve (45.00D, 7.5mm) to match the normal peripheral cornea. It can now be made in GP materials and is fit by varying the central sag of the lens until apical touch disappears or a small bubble is formed.

Later, McGuire lenses were used, with a steep center and a gradual flattening towards the periphery. The progressive flattening is achieved with a pentacurve: four peripheral curves that are 3, 6, 8, and 10D flatter than the base curve of the lens. The lens diameter is chosen according to the size of the cone, increasing as the cone diameter increases; that is, from 8.1mm for a centered or nipple cone to 8.6mm for an oval cone.

Today, corneal lenses with spherical curves can be designed using a contact lens axial edge lift program, with any diameter, back optic zone diameter and axial edge lift formed by multiple peripheral curves

Table 1. Example of multicurve trial set with fixed BOZD

9.4 TD																		
BOZR	7.99	7.90	7.80	7.67	7.50	7.34	7.18	7.11	7.03	6.96	6.89	6.82	6.75	6.68	6.62	6.55	6.49	6.37
BOZD	7.40	7.40	7.40	7.40	7.40	7.40	7.40	7.40	7.40	7.40	7.40	7.40	7.40	7.40	7.40	7.40	7.40	7.40
SC1	9.30	9.20	9.10	9.00	8.90	8.80	7.98	7.91	7.83	7.76	7.69	7.62	7.55	7.48	7.42	7.50	7.40	7.30
SCW1	8.00	8.00	8.00	8.00	8.00	8.00	8.00	8.00	8.00	8.00	8.00	8.00	8.00	8.00	8.00	8.00	8.00	8.00
SC2	10.30	10.20	10.10	10.00	9.90	9.80	8.98	8.91	8.83	8.76	8.69	8.62	8.55	8.48	8.42	8.55	8.40	8.30
SCW2	8.60	8.60	8.60	8.60	8.60	8.60	8.60	8.60	8.60	8.60	8.60	8.60	8.60	8.60	8.60	8.60	8.60	8.60
SC3	11.30	11.20	11.10	11.00	10.90	10.80	10.18	10.11	10.03	9.96	9.89	9.82	9.75	9.68	9.62	9.65	9.55	9.35
SCW3	9.00	9.00	9.00	9.00	9.00	9.00	9.00	9.00	9.00	9.00	9.00	9.00	9.00	9.00	9.00	9.00	9.00	9.00
PC	12.30	12.20	12.10	12.00	11.90	11.80	11.68	11.61	11.53	11.46	11.39	11.32	11.25	11.18	11.12	11.00	11.00	10.85
PCW	9.40	9.40	9.40	9.40	9.40	9.40	9.40	9.40	9.40	9.40	9.40	9.40	9.40	9.40	9.40	9.40	9.40	9.40
AEL	0.186	0.191	0.198	0.208	0.225	0.241	0.222	0.228	0.236	0.243	0.250	0.257	0.265	0.274	0.282	0.302	0.307	0.326

Table 2. Example of multicurve trial set with floating BOZD

9.4 TD																		
BOZR	8.00	7.90	7.80	7.70	7.60	7.50	7.40	7.30	7.20	7.10	7.00	6.90	6.80	6.70	6.60	6.50	6.40	6.30
BOZD	7.00	6.50	6.50	6.50	6.50	6.50	6.00	6.00	6.00	6.00	6.00	5.50	5.50	5.50	5.50	5.50	5.00	5.00
SC1	9.00	8.90	8.80	8.70	8.60	8.50	8.40	8.30	8.20	8.10	8.00	7.90	7.80	7.70	7.60	7.50	7.40	7.30
SCW1	7.60	7.10	7.10	7.10	7.10	7.10	6.60	6.60	6.60	6.60	6.60	6.20	6.20	6.20	6.20	6.20	5.80	5.80
SC2	10.00	9.90	9.80	9.70	9.60	9.50	9.40	9.30	9.20	9.10	9.00	8.90	8.80	8.70	8.60	8.50	8.40	8.30
SCW2	8.20	7.70	7.70	7.70	7.70	7.70	7.40	7.40	7.40	7.40	7.40	7.20	7.20	7.20	7.20	7.20	6.90	6.90
SC3	11.00	10.90	10.80	10.70	10.60	10.50	10.40	10.30	10.20	10.10	10.00	9.90	9.80	9.70	9.60	9.50	9.40	9.30
SCW3	8.60	8.55	8.55	8.55	8.55	8.55	8.40	8.40	8.40	8.40	8.40	8.30	8.30	8.30	8.30	8.30	8.00	8.00
PC	12.00	11.90	11.80	11.70	11.60	11.50	11.40	11.30	11.20	11.10	11.00	10.90	10.80	10.70	10.60	10.50	10.40	10.30
PCW	9.40	9.40	9.40	9.40	9.40	9.40	9.40	9.40	9.40	9.40	9.40	9.40	9.40	9.40	9.40	9.40	9.40	9.40
AEL	0.213	0.262	0.270	0.279	0.288	0.298	0.350	0.362	0.375	0.389	0.403	0.455	0.473	0.492	0.513	0.535	0.606	0.633

(Tables 1 and 2). The key is to ensure that the axial edge lift of the lens is high (higher than normal corneal design) enough to provide adequate clearance for corneas with higher eccentricity values. Diagnostic designs are available with fixed BOZDs with each BOZR, and either multicurve standard or steeper or flatter peripheries that can be ordered. Similarly, diagnostic designs with a floating BOZD with either multicurve standard or steeper or flatter peripheries have also been successfully fit.

Spherical center and aspheric periphery: With advances in manufacturing of GP lenses, lens designs have changed, and now aspheric periphery lenses are available. These designs offer the advantage of spherical central optics and an improved alignment in the periphery of the cornea. These designs also allow for a greater axial edge lift, as would be necessary with advancing keratoconus. The center of the lens and the periphery can be altered independently.

Aspheric contact lenses

Full aspheric designs, in which the lens flattens progressively from the center to the periphery, have become more readily available. Additionally, some designs offer aberration control, in which an aspheric surface on the front surface of the lens is added to help with spherical aberration. Due to closer alignment with the cornea, especially centrally, these lenses are fit steeper than a spherical lens with the same BOZD. Some designs allow you to dictate the eccentricity value of the aspheric back surface that you predict. Although the optic zone and the periphery of the lens can be adjusted independently, the lab will adjust the BOZR and power of the lens when the periphery of the lens is adjusted either steeper or flatter, due to the increase or decrease in overall sag of the lens. As opposed to having a fixed BOZD, some lenses are designed with a floating BOZD; that is, as the base curve of the lens steepens, the BOZD decreases in size, which allows easier refitting when the centered cones advance.

Semi- and mini-scleral contact lenses

Semi- and mini-scleral lens fitting and designs have evolved significantly with hyper-Dk GP lens materials, allowing for a more favorable oxygen delivery system. These lenses are designed to rest on the sclera and use spherical optics on the back surface in multiple zones, and some have aspheric optics on the front surface to reduce spherical aberration. They may have a pentacurve design, in which the base curve and first peripheral curve lie on the corneal zone, the next peripheral curve clears over the limbal area and the final two peripheral curves are tangent to the sclera. A more detailed discussion of these lenses can be found in Appendix D.

Piggyback lenses

Silicone hydrogel lenses with the steepest base curve available are generally used for piggybacking. Fluting of the edge of the lens may be evident if the lens is too flat, and a steep lens may have a trapped bubble at the limbus. Although a more rigid lens may seem more favorable to masking irregularity, it may not conform to the cornea, causing more visual disturbance by buckling with the blink. The lens should have a low plus prescription (+0.50D) to help center the GP lens. The base curve of the rigid lens used in the piggyback system may need to be adjusted by flattening the BOZR by 0.10mm. The axial edge clearance may also need to also be increased.

6. Lens Fitting

Choosing the correct lens design

General considerations

Contact lens options for keratoconus include (in order of increasing severity of the condition):

- Spherical (bicurve or tricurve) and aspheric gas permeable lenses
- Spherical multicurve GPs (specialty lenses) with spherical or aspheric peripheries
- Semi-scleral GP lenses

Advanced cases of keratoglobus, PMD and post surgical procedures may benefit from mini to full sclerals.

At this time, it is prudent to initiate the fitting of GP contact lenses, since it is inevitable that they will be necessary. Generally, patients are considered appropriate for contact lens wear when vision can no longer be adequately corrected with spectacles. The patient's need for functional vision is the primary determinant.

The fitting procedure should include the following:

- Case history
- Tear assessment
- Lids and lid margins assessment
- Keratometry
- Videokeratography
- Refraction
- Trial lens fitting
- Over-refraction
- Fluorescein pattern analysis

The pre-fitting evaluation should establish two important corneal parameters:

- The stage of the condition
- The size and location of the cone (in order to select the BOZD and TD)

The stage of keratoconus is determined by calculating the mean of the two K readings. If the mean K is less than 50.00D (6.75mm), the cone is considered to be in its early stage; if a mean of 50.00 to 56.00D (6.75 to 6.03mm) is found, the cone is advanced. Beyond 56.00D (6.03mm), the cone is considered to be severe. Videokeratography will aid in determining the shape, location and size of the cone. By the advanced stage, the conical area has acquired a definite shape, which may be classified as nipple (fairly centered and/or slightly nasal), oval (inferior and laterally displaced) or globus, which affects 75% or more of the cornea.

It is important to have trial lenses available for the fitting.

BOZR selection

To select the BOZR of the lens based on a particular BOZD and TD, keep in mind that as the K readings steepen, the sag of the cornea increases. A match must be achieved by increasing the BOZR as the corneal astigmatism increases and as the Ks increase.

Edrington et al. (*Optom Vis Sci* 1996) used average K reading as derived by traditional keratometry as a starting point in their study. They found no significant difference between the average K reading and the BOZR ($p = 0.3907$). This study did not analyze the final BOZR that was ultimately fit successfully, but instead used it as a starting point.

You can more accurately predict the BOZR of the contact lens for the keratoconic patient using the topographer and the simulated central K readings if you apply the fitting nomogram described in Table 3 or one suggested by the lens manufacturer.

Avoid the use of excessively flat BOZR, since they may increase corneal staining, scarring and distortion in addition to increasing discomfort. Too much apical clearance may also lead to corneal molding and transient compromise such as corneal edema, corneal staining, and epithelial lens imprint from an immobile lens. Corneal scarring, as well as poor VA, have also been reported.

Sorbara and Luong (1999) used instantaneous (or tangential) maps in fitting, as they best defined the apex decentration and shape of the cornea. The patients were categorized by the amount of corneal astigmatism (ΔK) and the final BOZR that was most successful was recorded. Equations were calculated based on the relationship of the final base curve relative to flat K. Table 3 summarizes the fitting nomogram that was derived for fitting keratoconic patients using the ΔK and flat K derived from the simulated K readings from the topographer. An example follows:

If subject 1 has a simulated flat K of 48.00D (7.03mm) as measured by the corneal topographer and $-3.00D$ of corneal astigmatism, the BOZR of the contact lens would be equal to $48.00 - (0.609 \times (-3.00)) = 49.83D$ (6.77 mm).

If subject 2 has a simulated flat K reading of 48.00D, but with $-7.00D$ of corneal astigmatism, $BOZR = 48.00 - (0.419 \times (-7.00))$ which equals 50.93D (6.62 mm).

More and more studies support the use of videokeratography readings to determine the base curve of contact lenses. Wasserman et al. (*CLAO J* 1992) found, after fitting 11 subjects with an aspheric lens, that the BOZR related most closely to the flattest K at the 5mm zone. Donshik et al. (*Trans Am Ophthalmol Soc* 1996) found that the final BOZR of the GP lenses most correlated with the average of the two most flat central semi-meridians at the 3mm central zone. Szczotka (*CLAO J* 1998) found that the axial steep simulated K readings (where the 5th, 6th, and 7th meridians are averaged) represented the best average spherical BOZR for the GP lenses.

Table 3. BOZR determination based on corneal astigmatism for 9.4TD

ΔK (D)	BOZR (D) (9.4TD)
-0.25D to -3.75D	Flat K (D) - 0.61 x (ΔK)
-4.00D to -7.50D	Flat K (D) - 0.50 x (ΔK)*
-7.75D to -16.75D	Flat K (D) - 0.35 x (ΔK)

*Approximately average K for 7.4mm BOZD

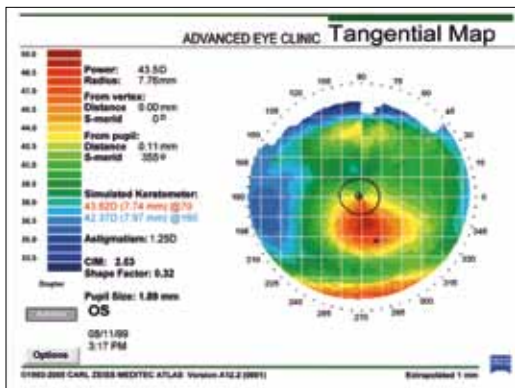


Figure 31. Early oval cone, topography map

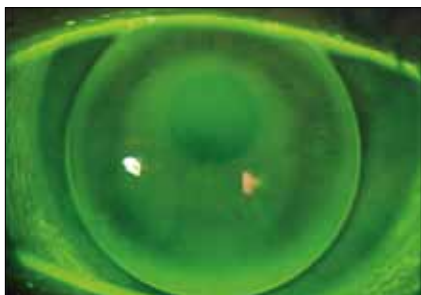


Figure 31a. Fluorescein, early oval cone

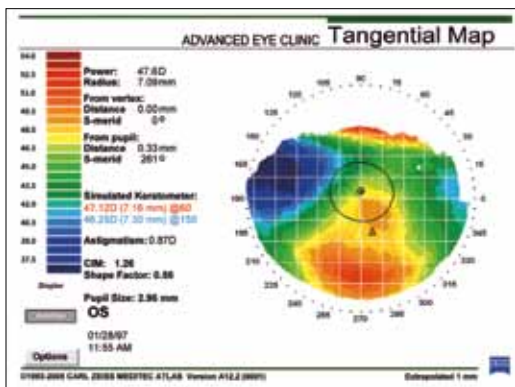


Figure 32. Moderate oval cone, topography map

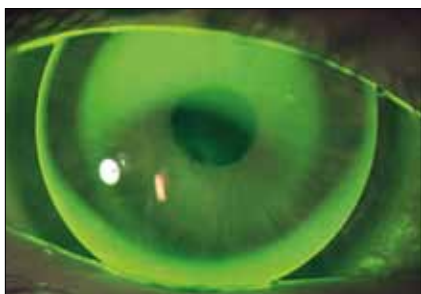


Figure 32a. Fluorescein, moderate oval cone

For the average amount of astigmatism (between -4.00 and -7.50 D), the nomogram indicates approximately the average of the simulated K readings as the selected BOZD, appropriate for a lens diameter of 9.4mm (0.419 to approximately equal to 0.50 (average of the flat and steep Ks)). For smaller lens diameters (e.g. 8.7mm), average K plus 0.2mm steeper is a good starting point and for larger lens diameters (e.g. 9.6 to 10.1mm), average K minus 0.2mm is a good starting BOZR, provided that the BOZDs are similarly smaller and larger, respectively. The final BOZR is determined by consulting the fluorescein pattern; a gentle three-point touch is desirable (Figures 31a and 32a). A harsh three-point touch may result in corneal scarring, excessive decentration, lens discomfort and corneal distortion.

These same rules can be applied for bi-aspheric lenses, except that the initial base curve should be 0.1 to 0.2mm flatter than that suggested by the nomogram, due to a closer conformation between the back surface of the contact lens and the cornea.

Power considerations

Early signs in the diagnosis of keratoconus are an increase in astigmatism and a change in axis of that cylinder. Normally, the patient is a myopic astigmat with either with-the-rule or oblique astigmatism in keratoconus, but with pellucid marginal degeneration, or the patient has high amounts of against-the-rule astigmatism with hyperopia (due to excessive flattening over the pupil). In both cases, this astigmatism becomes increasingly irregular and non-orthogonal, making retinoscopy difficult and further decreasing the patient's corrected acuity. An over-refraction can be obtained only once the GP lens is fit. The spherical back surface of the GP lens neutralizes the corneal irregularity by making the front surface of the tear film spherical, as long as the GP lens has no excessive flexure. Without the GP lens on the eye, the refraction is difficult to predict. Empirical fitting is increasingly less feasible with steeper cones.

Fitting procedures: selection of appropriate BOZD and TD

Previously, using small diameter lenses with small back optic zones meant that the lenses were fit with apical clearance (steep) and larger diameter lenses were fit with apical touch and lid attachment; however, most experts believe that these latter types of fits should be avoided. A three-point touch fitting method not only may improve the visual outcome but can help to maintain long term corneal health.

Predict the BOZD (and thus the TD) more accurately for a keratoconic patient by carefully examining the tangential topographic maps. The maps identify whether the patient has nipple, oval or globus type cones, the size of the thinning area and the location of the cone. Each topographic map has size indicators, where each tick mark is 1mm apart, aiding in the quick assessment of the size of the steepening area. Careful matching of this measurement to the BOZD of the contact lens will help to predict the appearance of the area of fluorescein pooling around the cone and the centration of the lens. Both of these parameters are essential in obtaining a successful fit of the keratoconic patient.

Close communication with your contact lens laboratory will help you understand the design of diagnostic lenses, allowing you to match the lens parameters with the type and size of cone you are fitting.

Fitting small diameter lenses (8.5 to 9.3mm)

Having identified the size of the cone and type of keratoconus, the lens back optic zone diameter can be selected. Small diameter lenses are most appropriate for the nipple or centered cone and early oval cones.

As the nipple cone progresses, smaller diameter lenses, with increasingly smaller back optic zone diameters (BOZDs), will have better centration and avoid air bubbles around the cone. A centrally located nipple cone occupies a smaller area which, as it progresses and steepens, becomes smaller and smaller (Figure 33a and 33b). The BOZD and BOZR thus should become smaller and smaller as the cone becomes steeper and steeper in order to match the cone and minimize the gap above

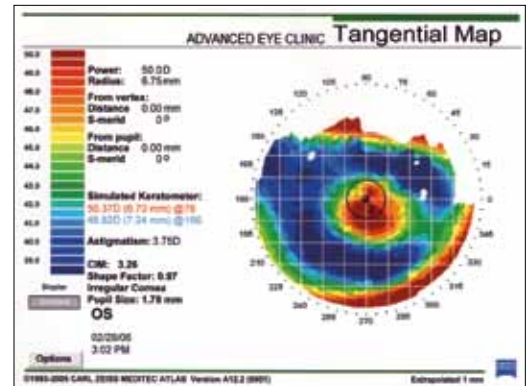


Figure 33a. Centered cone (early), topography map

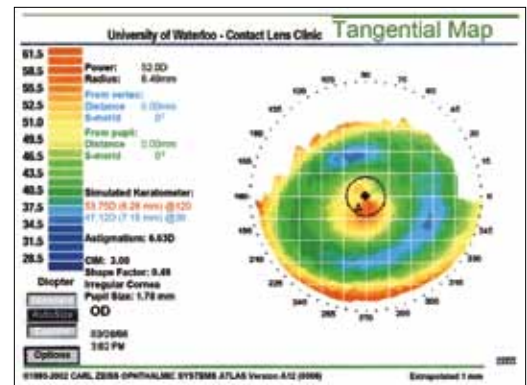


Figure 33b. Centered cone (late), topography map

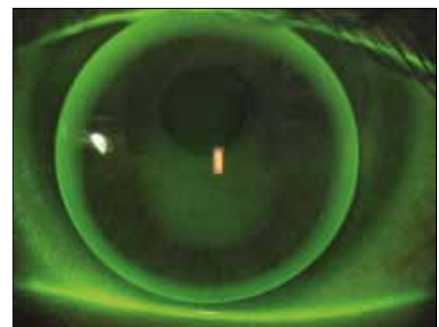


Figure 34. Fluorescein pattern of small diameter lens on a centered cone

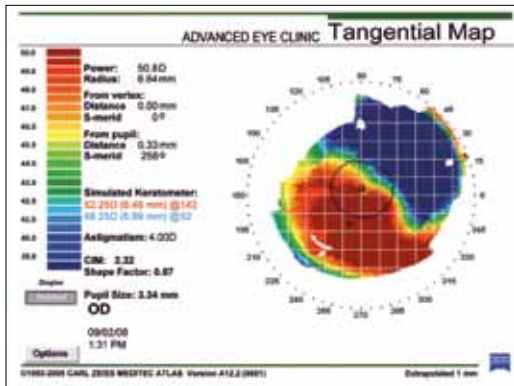


Figure 35. Severe oval cone (topography map)

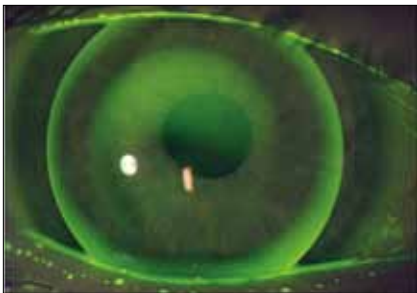


Figure 35a. Fluorescein, severe oval cone

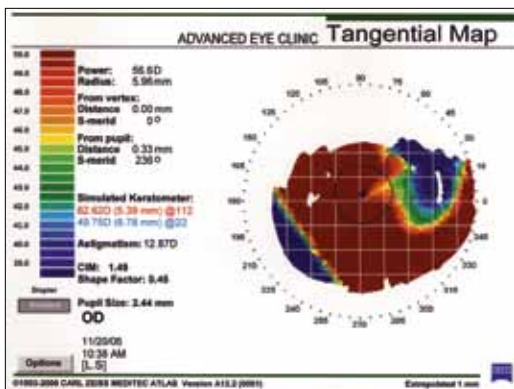


Figure 36. Globus cone (topography map)

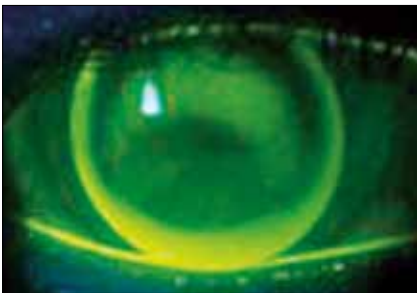


Figure 36a. Fluorescein, globus cone

and below it, where tears would pool. This will result in better lens centration and alignment with the cone (Figure 34).

Fitting medium diameter lenses (9.4 to 9.9mm)

Lenses with increasingly larger back optic zone diameters are a more appropriate fit for the progressing oval cone; promoting centration as the oval cone progresses and avoiding excessive clearance and bubbles around the cone.

Figures 31, 32, 35 and 36 demonstrate that less advanced keratoconic corneas may have smaller cones while more advanced keratoconic corneas have larger cones, if they are of the oval type. In order to choose the BOZD (and thus the overall lens diameter [TD]), look at the videokeratograph and assess the size or area of the cone. Select a larger BOZD and TD for larger (and usually steeper or more advanced) cones.

For these advanced oval type cones, contact lenses that are steeper centrally with larger BOZDs will more closely match this larger and steeper corneal cap, aligning with the corneal contour but without clearing the apex. The resultant apical contact should not be too severe.

Figures 31a, 32a, 35a and 36a demonstrate the slight three-point-touch that should be used to minimize corneal trauma at the apex yet to ensure that the irregular corneal surface is “regularized” or made spherical when corrected with a spherical GP lens to result in optimum visual acuity. Trial lens sets based on the McGuire™ multicurve design (available from most labs) or Soper designs have a constant BOZD for each lens diameter. For example: either 5.75mm BOZD/9.0 TD (for the incipient keratoconic) or 6.25mm BOZD/9.6 TD (for the moderate keratoconic) or 7.0mm BOZD/10.1 TD (for the advance keratoconic) can be prescribed.

Fitting large TD corneal (10.0 to 12.8mm) and corneal-sclerals (12.9 to 13.5mm)

Even larger diameter lenses with large BOZDs are fit to match the size of the advanced cone, avoiding either excessive clearance or excessive touch over the apex of the cone, which in turn encourages centration. Figure 36a is an example of a lens with a large BOZD lens and large TD on a large cone (globus) that results in good lens centration and gentle three-point touch. The lens is aspheric, with a large TD/BOZD

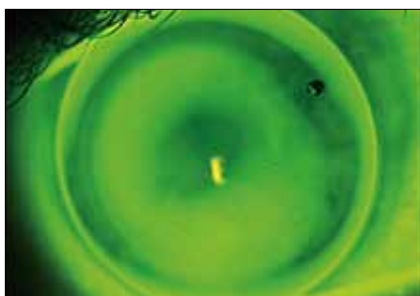


Figure 37. 10.4mm diameter

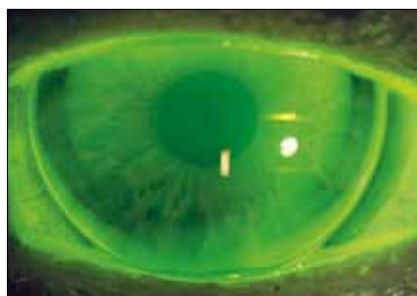


Figure 38. 11.2mm diameter (spherical)

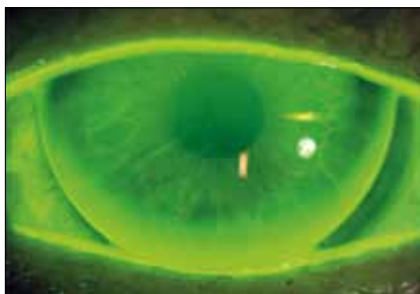


Figure 39. 11.2mm diameter (aspheric)

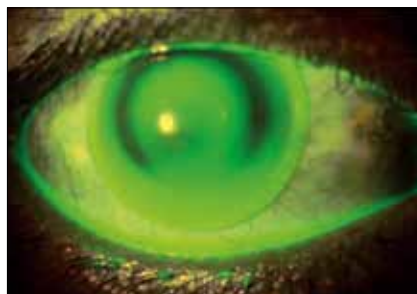


Figure 40. 13.5mm diameter

(10.2mm/9.2mm). Other choices (Figure 37) may also be appropriate with larger diameters such as 10.4mm.. For the globus cone, lenses with a larger diameter (11.2mm, for example) (Figure 38 and 39) or corneal-scleral lenses with TDs from 12.9 to 13.5 will achieve the desired effect (Figure 40). Table 4 summarizes the relationship between BOZD and cone size. Tables 5a and 5b link together the BOZD and the BOZR.

Fitting semi-sclerals (13.6 to 14.9mm TD) and mini-sclerals (15.0 to 18.0mm TD)

Since semi-scleral lenses are used to fit extremely irregular corneas due to advanced keratoconus and PMD, post-trauma, post-refractive ectasia, post-penetrating keratoplasty and post-RK, PRK and LASIK, it is useful to have an idea of the corneal sag in order to select the appropriate base curve or sag of the contact lens. It is ideal to ensure that the sag of the contact lens is greater than the sag of the cornea, to ensure that there is a continuous reservoir of tears across the entire back surface of the lens without too large a gap, which would invite bubbles.

Corneal sag can be measured directly using a Visante OCT instrument, which can be placed at any chord diameter (Figure 41). The Orbscan II can also provide an estimate of corneal sag at the chord of the HVID (“white to white,” as it is called), where the anterior chamber depth measurement is given. Added to the corneal thickness at the central point, this measurement would be an estimate of the corneal sag. Other topographers, such as the Medmont, provide a direct measurement of corneal sag. Also with any topographer offering an eccentricity value (e-value), the corneal sag may be calculated using the formula for prolate ellipses, which uses the shape factor ($p=1-e^2$), the K reading in that meridian (flat) and any semi-chord diameter.

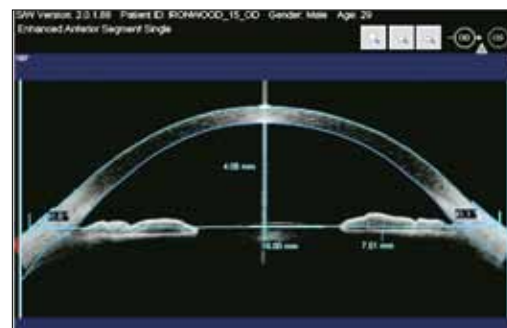


Figure 41. Sag with Visante

$$Sag = \frac{r - \sqrt{r^2 - p \left(\frac{chord}{2} \right)^2}}{p} \text{ where } r \text{ is the radius and } p \text{ the shape factor.}$$

Table 4. Relationship of cone diameter to BOZD/TD

Cone type	Cone diameters	BOZD ranges	LD ranges
Centered cone:			
Early	4.0 to 5.0mm	7.40 to 8.10mm	9.4 to 9.6mm
Moderate	2.8 to 3.9mm	5.00 to 7.30mm	8.8 to 9.3mm
Late	2.0 to 2.7mm	3.00 to 4.90mm	8.0 to 8.7mm
Oval cone:			
Early	2.0 to 4.0mm	5.25 to 7.50mm	8.5 to 9.6mm
Moderate	4.2 to 5.0mm	7.60 to 8.10mm	9.8 to 10.1mm
Severe	5.2 to 7.0mm	8.20 to 9.40mm	10.2 to 11.4mm
Globus cone	>7.0mm	9.20 to 9.60mm	10.2 to 11.4mm
PMD:			
Early	5.0 to 7.0mm	8.20 to 9.40mm	10.2 to 11.4mm
Late	7.2 to 9.0mm	9.40 to 10.50mm	11.4 to 18.2mm

Table 5a. BOZR determination based on floating BOZD

Floating BOZD	BOZR (mm)
3.3–4.3mm	Average K (mm) – 0.4mm
3.9–4.6mm	Average K (mm) – 0.35mm
5.1–6.1mm	Average K (mm) – 0.3mm
6.2–7.2mm	Average K (mm) – 0.2mm
7.4–8.0mm	Average K (mm)
>8.1 BOZD	Average K (mm) + 0.2mm

Table 5b. BOZR determination based on fixed BOZD

Fixed BOZD/LD	BOZR (mm)
6.5–7.2/8.5–9.0mm	Average K (mm) – 0.2mm
7.3–7.5/9.2–9.6mm	Average K (mm)
7.6–8.1/9.8–10.1mm	Average K (mm) + 0.15mm
8.2–8.6/10.2–10.6mm	Average K (mm) + 0.2 to 0.3mm
8.7–9.4/10.8–11.4mm	Average K (mm) + 0.4

Having the sag of the cornea, a semi-scleral lens with slightly greater sag can now be selected, to ensure corneal clearance. If the lens is labeled with radius measurements, the sag of the cornea would be calculated at the BOZD of the contact lens and then this value can be converted to radius.

$$r = \frac{\left(\frac{\text{chord}}{2}\right)^2 - p(\text{sag})^2}{2(\text{sag})}$$

The manufacturers' fitting guides will also suggest an initial trial lens based on the progression of the cone.

To achieve mid-peripheral pooling, the mid-peripheral curves of the contact lens (either two or three spherical curves or an aspheric zone) will have to be:

- flattened (if there is no clearance), or
- steepened (if there is excessive clearance with bubbles)

The final portion of the lens, the scleral zone, can only be partially viewed with newer OCT instruments such as the RT-Vue OCT (Clarion Medical Tech), the Visante OCT (Zeiss Meditec, CA) and with slit lamp profile photography. Identify a tangential (i.e. aligned) scleral zone by evaluating the conjunctival blood vessels for impingement of their rate of flow and with fluorescein.

See Figures 42, 42a, 42b and 43 for examples of semi-scleral lenses.

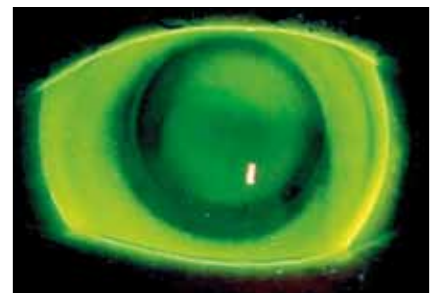
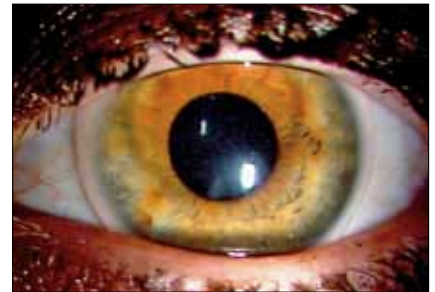
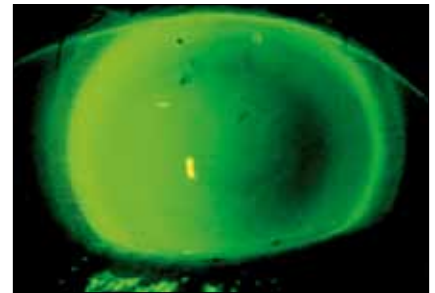
Peripheral lens design

Determining axial edge lift (AEL)

The final parameter relevant to the lens performance and ensuring an unaltered corneal physiology is the peripheral curvature system of the lens described as the axial edge lift (AEL) of the lens and on eye as the axial edge clearance (AEC) (Figure 44). The axial edge clearance (AEC) is described as the tear layer thickness (TLT) between the contact lens and the cornea.

For incipient keratoconus, use lenses with an axial edge lift (AEL) of 120 microns (standard) or standard aspheric lenses (e.g. Boston Envision™) with slightly higher AELs. This amount of AEL is based on an average e-value (eccentricity of 0.45 to 0.55). Once the keratoconus reaches an advanced stage, multicurve designs need to be fit, requiring either smaller or larger than average BOZDs and higher AELs (from 200 to 350 microns initially), as the curvature of the cone increases (and therefore its sag increases) in addition to a rapid flattening out to the periphery. Then, AELs up to 650 microns or more may be necessary as the eccentricity values of the keratoconic cornea increase (from 0.75 to ≈1.00), with increasing central steepening.

Diagnostic trial lenses have standard peripheries with proprietary peripheral designs yet higher-than-average AELs. Trial fitting of these



Figures 42, 42a and 42b. 15.8mm diameter

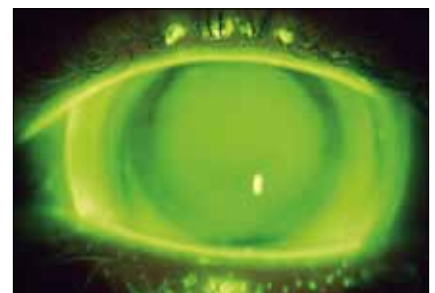


Figure 43. 18.2mm diameter

lenses may result in a fluorescein pattern showing a central, gentle three-point touch but insufficient (more commonly) or excessive peripheral clearance. It is only these cases in which the peripheral edge lift may need adjusting. Until the central pattern is ideal, the AEL of the lens should not be changed since the peripheral clearance may simply be the result of an excessively steep or flat lens. Assuming that the lens-cornea base curve (BOZR) relationship is ideal, the periphery may be reordered in regular steps (step #1, #2 or #3 etc.) that are either steeper or flatter than the standard.

When adjustments are made to the periphery of lenses with a very small BOZD (3.7mm to 5.1mm), the central fit of the lens will be affected. A steeper periphery will make the central fit appear steeper, due to the increased sag, and the lab will automatically flatten the BOZR (by 0.05mm, generally) to compensate for this change in sag. The power of the lens will also be compensated for at the same time, by $-0.25D$. A flatter periphery will result in a reduction of the sag visible with the fluorescein pattern, due to the small BOZDs and so, similarly, a steeper BOZR will be given (by 0.05mm) and less minus power added ($+0.50D$). A repeat order would indicate that these new parameters have already been adjusted in order to avoid the need for further compensation.

Generally, lenses with larger BOZDs ($>6.25mm$) may not need to be compensated for due to the change in sag, since the fluorescein pattern may be unaffected by the sag change caused by the increase or decrease of the peripheral edge lift. These lenses may be ordered with increased or decreased peripheries and AEC, and the BOZR is maintained. When this new lens is trial fit, the fluorescein pattern would be assessed to determine whether any compensation is necessary.

Toric or unequal peripheries




Figure 45. Unequal peripheries

Newer lens designs are based on topographical data able to aid in assessing whether irregular astigmatism extends to the peripheral cornea. These designs have toric peripheries or peripheries in which a section of the lens may be manufactured with a lower AEL than the rest of the lens. A toric periphery may be 1.0mm wide with a 0.8mm difference between the two meridians. The BOZR will be steepened by 0.05mm and the power compensated by an additional $-0.25D$ when this change is made.

“Toric” peripheral designs are indicated when topography indicates that the much steeper inferior cornea is inferiorly displaced, causing the lower edge of the lens to lift up and irritate the lower eye lid. Lenses may be designed with a standard periphery at 90° and steeper periphery at 270° with a 1 to 1.25 prism base at 270° to stabilize the lens in position. Other designs have a superior zone with a standard periphery, and the inferior quadrant is made steeper with the nasal and temporal zones as transition zones with intermediate AELs.

These lens designs are also useful in cases of pellucid marginal degeneration, in which the thinning of the cornea occurs much more inferiorly than it does in a keratoconic cornea,

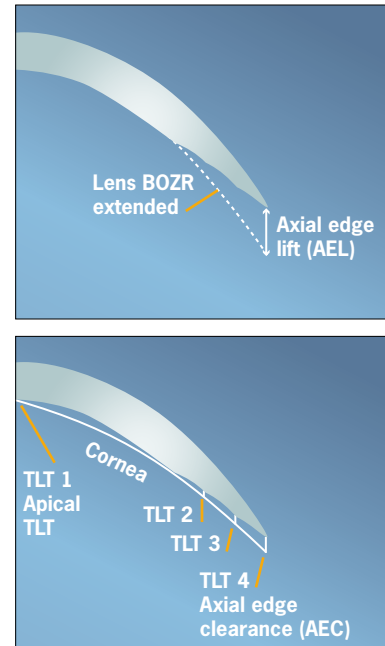


Figure 44. AEL and AEC of contact lens

resulting from excessive clearance on the inferior edge of the lens (Figure 45).

Evaluation of appropriate fit



Figure 46. Wratten Boston filter

Fluorescein pattern

All fluorescein pattern evaluation must be conducted using a cobalt filter on the slit lamp, with the use of a Wratten #12 enhancing yellow filter to ensure maximum excitation (Figure 46). The wetted fluorescein strip should be applied to the bulbar conjunctiva to minimize the amount

of fluorescein that comes into contact with the front surface of the lens. Since most peripheries of trial lenses have standard edge lift, more advanced cones with higher e-values will require flatter peripheries. Pump some tears under the tighter lower edge of the lens to evaluate the central fluorescein pattern. It is also important to allow the lens to settle on the eye for 5 to 20 minutes, especially for those lenses with scleral support, since the lens may flex and move closer to the cornea with time.

Three-point touch (divided support)

It is generally accepted that a gentle three-point touch on the verge of apical clearance is the fitting appearance to be achieved within the central portion of the lens. The location of this touch is dependent on the location of the apex of the cone. It will be centrally located with a nipple cone, whereas with an oval cone, this area will be decentered inferiorly or inferior-laterally. The two other areas of touch are usually located along the flattest meridian, usually horizontally in keratoconus and possibly vertically with early PMD. The peripheral clearance of 0.5 to 0.7mm in width can be achieved with flatter-than-standard peripheries (Figure 47).

Apical touch

There is evidence that apical touch induced by too flat a base curve (or too low a sag) may cause apical damage including whorl staining and scarring. Large diameter lenses need not be fit flat with lid attachment, as originally understood: Use the increased sag to fit the larger cone without severe apical touch. Figure 48 shows the impact of a flat fitting lens with corneal apical damage. This type of fit should be avoided.

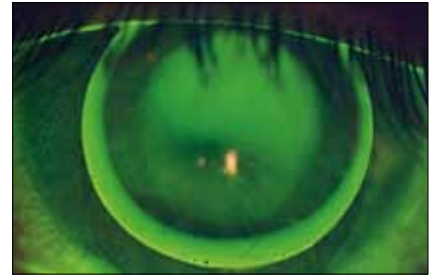


Figure 47. Three-point touch (divided support), fluorescein

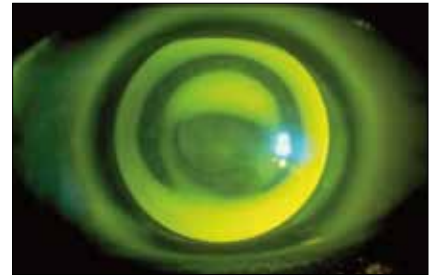


Figure 48. Flat (central touch), fluorescein

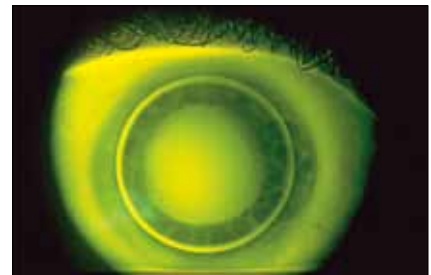


Figure 49. Steep (apical clearance), fluorescein

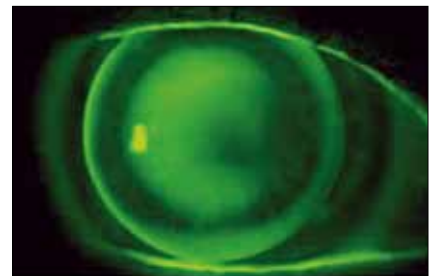


Figure 50. Ideal peripheral edge clearance (spherical lens)

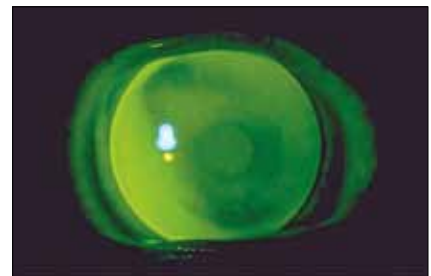


Figure 51. Ideal peripheral edge clearance (aspheric lens)

Gaining an understanding of the eccentricity of the cornea and its increase in cases of keratoconus, which you can see via topographical maps, will help explain the reasons for either increasing or reducing the axial edge lift of the lens to provide an ideal amount of peripheral clearance.

Apical clearance

Excessive apical clearance should also be avoided. Bubbles may be trapped within the optic zone area and interfere with comfort and acuity. The poorer acuity can also be attributed to lens flexure, which causes the front surface of the tear layer to become toric and thus the lens will no longer correct the corneal irregularity due to the presence of this residual astigmatism (Figure 49). With excessively steep lenses, particularly on corneas with a high degree of astigmatism, corneal curvature may steepen and corneal molding may occur, leading to a myopic shift.

Ideal axial edge clearance

Once the ideal central fluorescein pattern has been achieved, the mid-peripheral and peripheral fluorescein pattern can be assessed. Ideally, the mid-periphery should be tangential to the corneal mid-periphery in an alignment pattern for spherical peripheral curves (Figure 50). If the peripheral curves are aspheric, this alignment is more evident, with some diffuse clearance feathering to the lens periphery (Figure 51).

The periphery of the contact lens should have 100 to 120 microns of clearance from the peripheral cornea. Slightly more clearance is warranted in larger diameter lenses with flatter peripheral curves (i.e. increased axial edge lifts), and slightly less clearance (i.e. decreased axial edge lifts) is necessary with smaller diameter lenses. This ideal lens clearance is necessary to ensure lens movement, tear exchange and debris removal from under the lens, in addition to controlling lens centration.

A ring of clearance 0.7mm in width would be ideal and one that is uniform in all directions. If the lens BOZD and TD are large enough with large, low cones, the bottom edge of the lens should be tucked under the lower eyelid with the peripheral clearance being uniform, 360°. To achieve the ideal clearance, either flattening or steepening the AEL is necessary. If necessary, alter the axial edge lift in a single quadrant of the lens to achieve uniformity of edge clearance.

Minimum edge clearance

Minimum or no edge clearance for lenses of any diameter is not acceptable; it may lead to peripheral impingement causing corneal molding, staining and reduced or no lens movement, leading to entrapment of stagnant tears and debris and causing edema and inflammatory responses. Minimum clearance lenses tend to sit centered over the cone apex, which may be decentered inferiorly and temporally, or nasally (Figure 52).

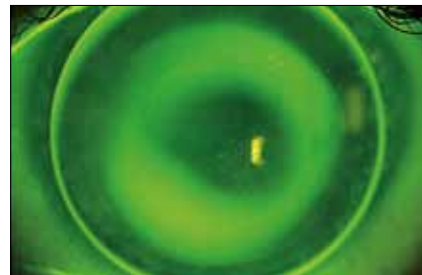


Figure 52. Minimal edge clearance

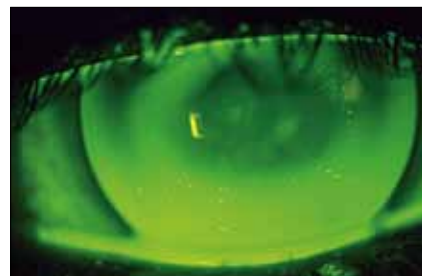


Figure 53. Excessive edge clearance (sitting on lower lid)

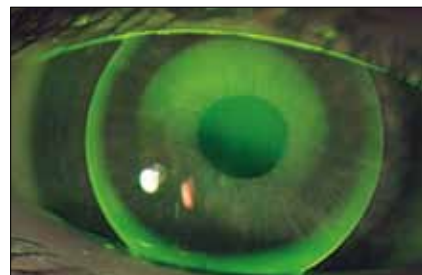


Figure 54. Centered lens

Excessive edge clearance

Excessive edge clearance causes irritation and a foreign body sensation. It may cause the lower lens edge to sit above the lower eyelid, threatening to eject from the cornea on extreme lateral gaze or repeated dislodging of the lens (Figure 53). The upper eyelid may also draw the lens up to a lid-attached position, which is also not desirable, since it will cause regional flattening over the apex of the inferiorly displaced cone.

Lens centration and movement

Ideally the lens should center, as with any interpalpebral-fitting contact lens (Figure 54). Centration can be achieved with an ideal fluorescein pattern and proper lens diameter chosen to match the diameter of the cone (that is, larger lenses with larger cone diameters). Lens movement is also necessary to promote normal corneal physiology. The movement of the lens will range from 2.0mm for smaller diameter lenses to 0.5mm with very large diameter corneal lenses. Corneal-scleral and semi-scleral lenses will have minimal to no lens movement depending on a tear pumping action by the eyelids on the front surface of the flexing apical clearance lens, to exchange tears under the lens. Use the push-up method to ensure that the lens is free from any contact points on the sclera.

Over-refraction

Once the fit of the trial lens has been optimized, an over-refraction should be completed, with the lens in place, to find the final lens power. The aid of an autorefractor is helpful, since retinoscopy will be difficult due to the scissors reflex. Due to potential difficulty in determining the cylinder power and axis, establish a spherical over-refraction first. If there is definite evidence that residual astigmatism should be corrected and improves the acuity, this over-refraction can be put into a pair of spectacles to be worn over the contact lenses (especially for the presbyopic keratoconic patient).

Fluorescein simulations from topography maps

Using the videokeratoscope, which more accurately defines the shape of the cornea, and the fitting nomogram would be an advantage in finding the final BOZR, BOZD and TD quickly. Topographer software invites you, the practitioner, to install your own fitting nomogram within a contact lens fitting module for the specific lens types that you select under “Doctor Preferences.” With some expertise, this nomogram could be installed for keratoconic multicurve lens designs on any topographer. Predicting the initial and/or final lens parameters by using the topographer and this fitting nomogram substantiates further their use in optometric practice. The topographers also offer simulated fluorescein patterns that can be manipulated to demonstrate a steep, flat or ideal central lens fit. Some examples are shown in Figures 55, 56 and 57 (Focal Points fluorescein simulation).

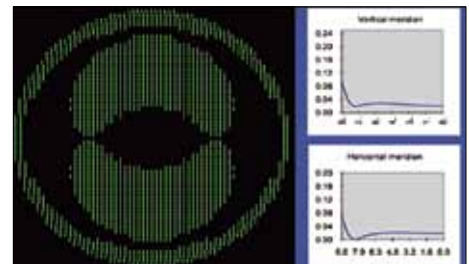


Figure 55. Ideal simulated fluorescein pattern

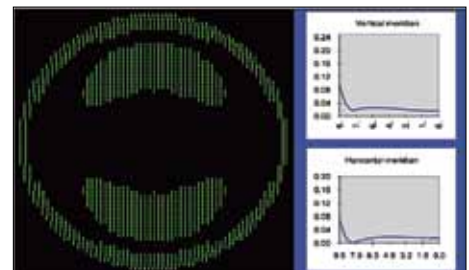


Figure 56. Too flat simulated fluorescein pattern

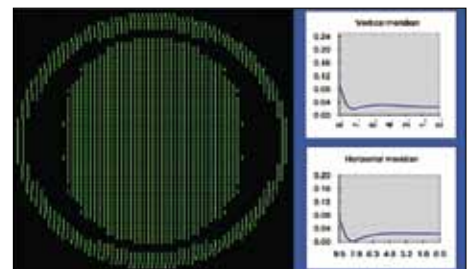


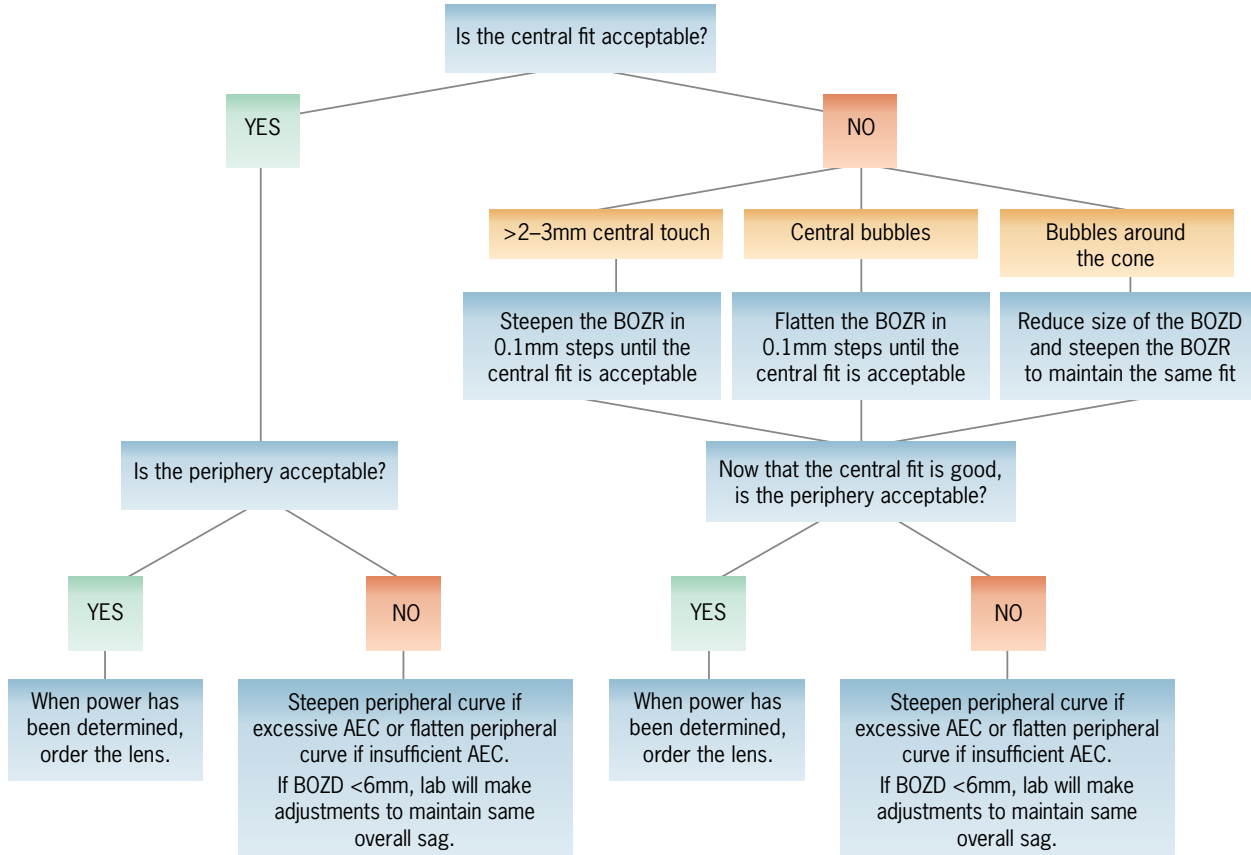
Figure 57. Too steep simulated fluorescein pattern

7. Follow-up and Management Strategies

Follow-up procedures and visits

Keratoconic patients generally require more frequent follow-up and aftercare visits than other contact lens wearers. They are also most loyal and appreciative of your care. They will refer patients to you, as they see you as a specialist. Alterations in lens parameters are also likely to be needed on a regular basis, particularly while the condition is in its progressive stage.

After the initial lens delivery and teaching appointment, consider a one-week, one-, two- and three-month visit, followed by three-month visits for the first year. Visit frequency may decrease in subsequent years depending on the rate of progression of the disease. At each of the three-month follow-up visits, visual acuity (high- and low-contrast), over-refraction, corneal topography, lens surface and fit assessment with fluorescein and biomicroscopy with and without lenses should be performed. A discussion of the vision, comfort, foreign bodies and dryness symptoms should be addressed at each visit. Particular attention should be paid to the degree of central lens/apex touch, which should be gentle with a small amount of apical clearance and should not have an obvious central touch. If this relationship has changed, the lens should be refit: either steepened with the same design or changed to a larger diameter lens, especially if the size of the cone has increased significantly in size. The following flow chart guides you through the fitting procedure at the first follow-up visit.



Any episodes of severe pain need to be reported to you immediately as they may indicate hydrops and the appropriate management and referral is necessary.

They should seek care from a corneal specialist if you cannot be contacted. These episodes may be a result of corneal hydrops (breakdown of the endothelial pump resulting in massive edema and pain) and early detection is key to a more favorable resolution (Figure 58). Early diagnosis of corneal hydrops may be treated by lens discontinuation and hypertonic drops such as Muro 128 (B&L), followed by referral to a corneal specialist.

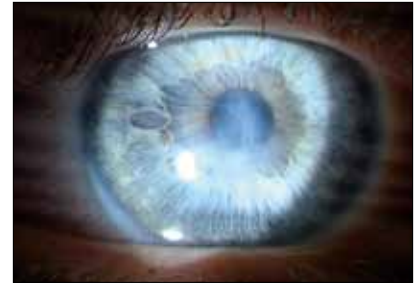

Figure 58. Corneal hydrops

Dependent on its resolution and any central corneal scarring that may remain, a penetrating keratoplasty may be considered. Lens replacement, if not for changes in fit parameters or power, may be made on an annual basis, to ensure a deposit- and scratch-free environment.

Complications necessitating lens changes

The following table lists clinical observations that would necessitate a refit:

Observations	Possible significance (refit necessary)																			
	Increased corneal thinning	Poor lens edge	Increased corneal deposits	Excessive lens movement	Increased corneal steepening	Tight periphery	Flat periphery	Increased corneal eccentricity	Flat lens/fit	Excessive edge clearance	Increased irregular astigmatism	Increased aberrations	Lens decentration	Lens diameter too small	Increased dryness	Large BOZD	Small BOZD	Increased corneal scarring	Corneal edema	
Increased corneal scarring	■				■															
Increased central touch					■															
Reduced axial edge clearance						■		■												
Increased lens dislocation								■	■											
Reduced lens movement													■							
Increased 3&9 staining														■	■					
Increased central staining								■												
Increased central bubbles																■				
Increased peripheral bubbles							■			■										
Reduced vision											■	■							■	
Increased flare													■					■		
Increased haloes																				■
Increased fluctuating vision		■	■										■							
Difficulty with lens removal					■															
Lens discomfort or irritation		■					■													

Altering lens design

Changing BOZR

- When steepening or flattening the BOZR, ensure that you have converted the radius from millimeters to diopters in order to adjust the power of the contact lens to compensate for the change in tear layer.
- Make changes to the BOZR in 0.1mm steps to ensure that you notice any significant changes in fit.
- Steepen the BOZR when the central touch pattern is unacceptable and apical corneal damage is evident or possible.
- Flatten the BOZR when central bubbles are present and do not disappear with the blink, interfering with vision, or when there is evidence of lens binding.

Changing BOZD

- When increasing or decreasing the BOZD, ensure that you compensate for the change in lens sag by either flattening or steepening the BOZR, respectively, to maintain the same fitting relationship. No change in lens power is then necessary.
- Increase the BOZD (and maintain the same BOZR) when the cone diameter has increased, to better align with the topography. This increases the sag of the lens.
- Decrease the BOZD (and maintain the same BOZR) when there are bubbles over the pupil, to reduce the clearance around the cone and better align with the size of the cone. In these cases, adjust the power of the lens due to the change in lens sag and thus the tear film.
- Steepening of BOZR requires an increase in minus power and vice versa.

Changing TD

- Increasing or decreasing the lens diameter without making a change to the BOZD will result in an increase or decrease in the peripheral clearance, unless you ask that the AEL be maintained.
- Increasing the lens diameter may be helpful when
 - the cone diameter has increased,
 - the lens begins to decenter,
 - there is evidence of 3&9 staining.
- Decrease the lens diameter if the lens edge approaches the limbus without overlapping it or to reduce the weight of the lens; an edge that sits directly on the limbus may cause irritation.

Changing AEL

- Only adjust the AEL of the lens when the central fluorescein pattern is ideal and demonstrates an ideal fitting relationship. Increasing or decreasing the AEL of a lens that has a small BOZD greatly affects its overall sag, which then needs to be compensated for and adjusted.
- When increasing the AEL to improve tear exchange at the lens periphery, the BOZR should be steepened (usually by 0.1mm) and the power should be adjusted to include the appropriate amount of increased minus power with small optic zone diameter lenses. If the AEL is reduced (i.e. if the lens is sitting too high or the lens edge is irritating), the reverse is true.

Changing sectoral AEL

- Usually, adjustments to the inferior sector of the contact lens do not affect lens fit. The addition of prism ballasting to maintain its inferior position may affect comfort.

- Toric peripheries do not affect the fit and may increase the comfort of the lens.
- Consider a sectoral adjustment in cases of PMD, in which the inferiorly displaced cone results in the lower edge of the lens to cause irritation to the lower lid and where a larger diameter/larger BOZD lens did not allow the lower lens edge to sit under the lower lid.

Changing center thickness

- Consider increasing the center thickness of the lens, if there is lens flexure that is not the result of too steep a fit but rather from too thin a lens. Usually a change of 0.02mm is sufficient to reduce 0.75D of lens flexure.
- Ensure that you are using a lens material of high enough oxygen permeability to avoid reducing the oxygen transmission too significantly.

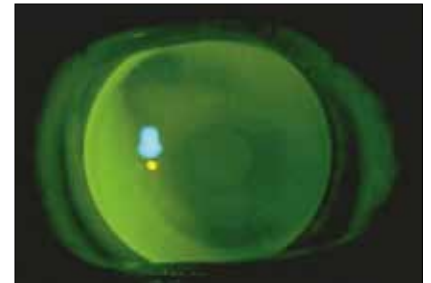
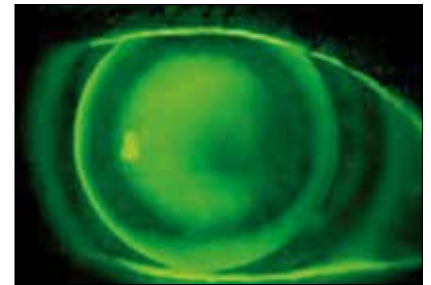
Changing lens power

- When increasing the minus power of the lens over 4.00D, consider lenticulating the lens or increasing the amount of lenticulation.
- To correct any residual astigmatism, front toric lens designs may not work, due to the irregularity of the astigmatism.

Refitting with different lens and/or design

Spherical to aspheric BOZD

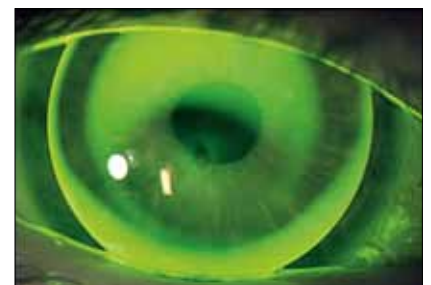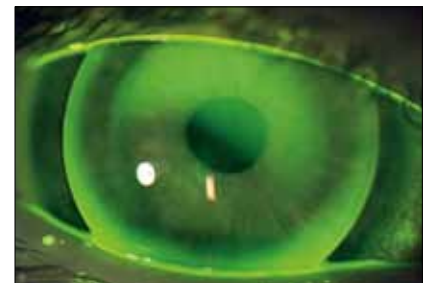- When refitting from a spherical optic zone design to an aspheric optic zone design, adjust the BOZR so that it is 0.10 to 0.15mm flatter.
- Compensate for lens power by adding 0.50 to 0.75D more plus. The reverse is true when changing from an aspheric optic to a spherical one (Figures 59a and b).



Figures 59a and 59b. Sphere to asphere center

Spherical to aspheric lens periphery

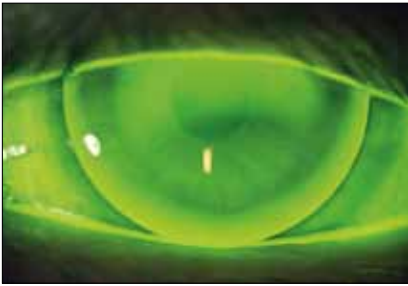
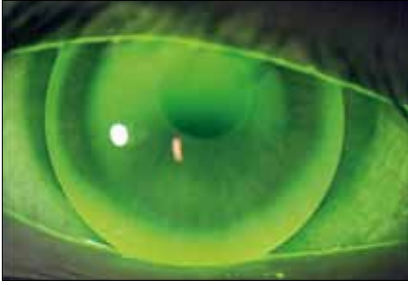- When converting from a spherical multicurve periphery to an aspheric periphery, you may need to increase axial edge clearance. The aspheric periphery will otherwise fit closer to the corneal contour and so may need flattening (and vice versa when going from an aspheric to a spherical peripheral design) (Figures 60a and b).



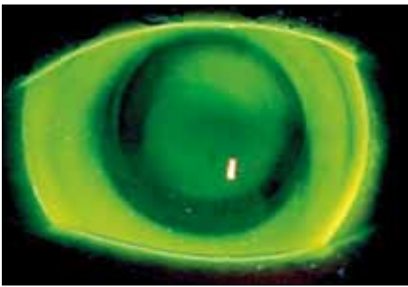
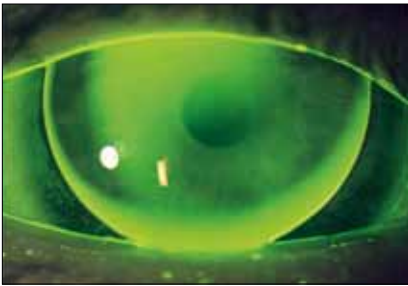
Figures 60a and 60b. Sphere to asphere periphery

Fixed to floating BOZD

- When changing from a lens design that has a fixed BOZD to a design that has a floating one, you may need to increase or decrease the BOZD depending on the radius of the lens.
- Steeper lenses have smaller BOZDs in floating BOZR designs.
- To maintain the same fitting relationship, you may need to compensate for the BOZD for by either flattening or steepening the BOZR to maintain the same fitting relationship (if the BOZD is larger or smaller, respectively) (Figures 61a and b).



Figures 61a and 61b. Fixed to floating



Figures 62a and 62b. Corneal to scleral

Corneal lenses to semi-scleral designs

- Consider that the change in lens diameter has increased the sag of the lens considerably, and you will need to compensate for it with a much flatter BOZR. The lens is now fit to the sag of the cornea rather than base curve. Your gentle three point pattern is replaced by a fluorescein pattern of slight apical clearance across the entire cornea while the lens rests on the sclera (Figures 62a and b).

8. Complications

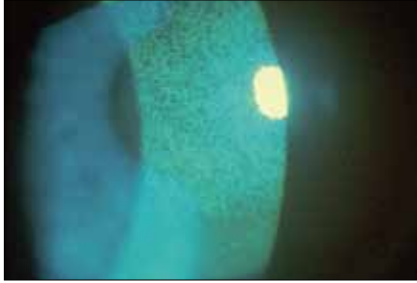


Figure 63. Solution toxicity

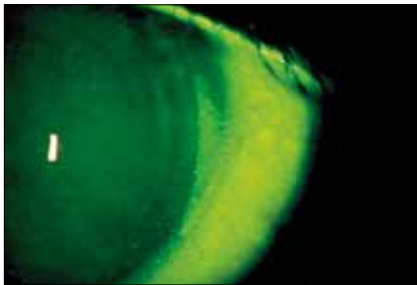


Figure 64. 3&9 staining

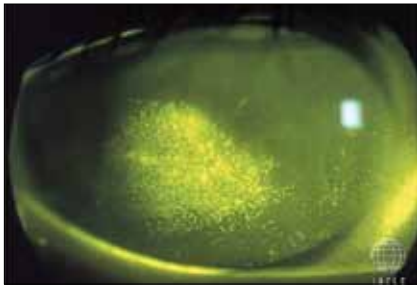


Figure 65. Coalesced patch staining

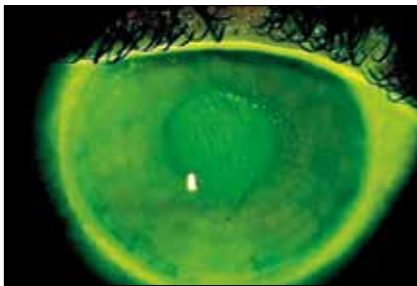


Figure 66. Whorl staining over the cone: too small diameter and steep (decentered)

Corneal staining

Many forms of corneal staining may be identified with the wear of keratoconic GP lenses including:

Solution toxicity staining

Solution toxicity staining is rare with GP lenses, but may occur with certain preservatives, including chlorhexidine, thimerosal or, rarely, polyhexanide and polyquad. This reaction is dependent on the concentration of these components and may cause diffuse corneal staining in the area underneath the contact lens (Figure 63). The presence of this staining indicates that the care system needs to be changed and/or a saline rinse may be necessary prior to lens insertion. Consider also that lens lubricating drops and tear supplements may cause this response, in which case non-preserved tear supplements may be needed.

Three and nine o'clock staining

Three and nine o'clock staining results from a combination of many factors related to lens fit and the ocular surface. Four and eight o'clock staining are commonly seen when the lens is sitting low and is immobile, aborting a complete blink (Figure 64). If the lens has a thick edge profile or high axial edge clearance, the area adjacent to the lens periphery will dry and cause staining. If the lens is too small, the exposed cornea will dehydrate and present as staining, particularly in dry eye patients. The keratoconic patient may have dry eye associated with atopic disease and lid gland dysfunction, both of which contribute to peripheral staining. To manage this response,

- increase lens diameter
- lenticulate the lens front surface to reduce the edge thickness
- ensure the proper amount of edge clearance and lens centration

Proper lid hygiene and dry eye management is also extremely important to ensure adequate wearing times.

Patch or linear staining due to an abrasion or foreign body

Coalesced patches of staining may be seen where the lens back surface may be rubbing or irritating the corneal surface, usually as a result of too much contact. Combined with the entrapment of foreign bodies, these conditions can disrupt the epithelium (Figure 65). Both corneal

topography and the back surface topography of the lens should be considered in trying to resolve this issue. Solutions may include cleaning the back surface of the lens, smoothing out the junctions of the peripheral curves or trying an aspheric design.

Apical staining

Apical staining (usually in a whorl pattern) arises when the contact lens is too flat with apical touch and has excessive lens movement (apical rotation) (Figure 66). This constant irritation may lead to scarring (Figure 67). Relieving the pressure of the lens from the apex of the cone will help in these cases.

Dimple veiling

Dimple veiling is made up of the impression made by air bubbles on the corneal surface. They are of no long-term significance physiologically, but may have associated symptoms of discomfort. They may interfere with vision, if present centrally. Within one half hour of lens removal, the imprints of the bubbles disappear from the corneal surface. To resolve this condition, reduce the area of clearance by:

- decreasing the amount of apical clearance (if the bubbles are located over the cone)
- reducing the BOZD (if the bubbles are located around the cone)
- reducing the axial edge clearance (if they are located at the lens periphery) (Figure 68)

Vision

Lenses with excessively large BOZDs compared to the size of the cone will have excessive apical clearance and may also have air bubbles over and around the cone, interfering with visual performance. Lenses in which the BOZD is too small may be decentered, in addition to having flare and decreased visual performance. Matching the BOZD with the diameter of the cone may resolve these visual issues.

With excessive apical clearance, the lens will flex on the cornea causing fluctuating blur with the blink. The lens should be aligned with the apex and if there is still flexure after adjusting the BOZR, the center thickness of the lens should be modified. Lenses need not be fit with excessive touch in order to achieve adequate vision (Zadnick (CLEK), Sorbara et al.). Minimal apical touch will likely result in the best acuity.

The keratoconic cornea has abnormally high levels of higher order aberrations, notably spherical aberration and coma, which degrade vision. An attempt to correct some aberrations with front surface aspheric optics may benefit some patients.

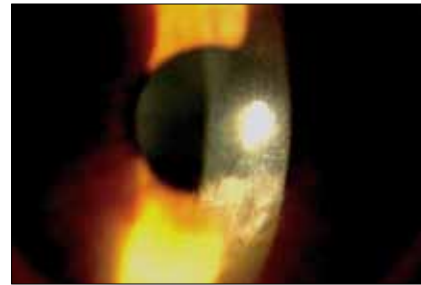


Figure 67. Scarring of the cone

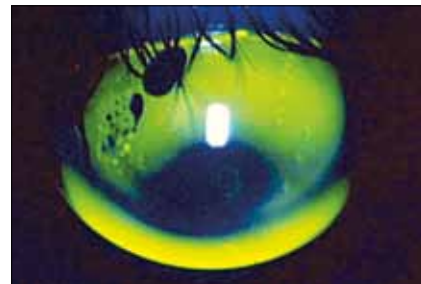

Figure 68. Dimple veiling

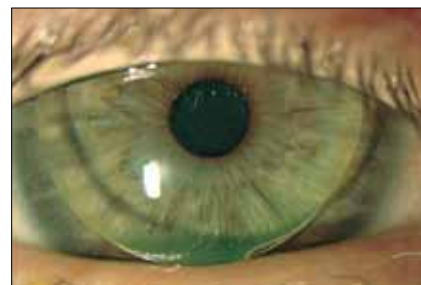

Figure 69. Too flat periphery (decentered)

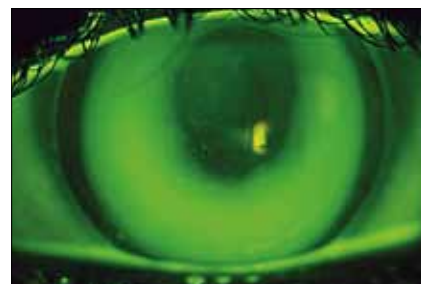

Figure 70. Too steep periphery (decentered down)

Lens decentration

When a lens with a small BOZD is paired with a large cone, its reduced sag will make the lens slide around and decenter more easily. Similarly, lenses with loose peripheries (high edge clearance) will decenter sometimes being held up by the upper eyelid (Figure 69). This loose fit affects visual performance and may lead to a poorer physiological response. Lenses with low axial edge clearances and excessive apical clearance often decenter downwards, towards the location of the cone apex, leading to incomplete blinking and dryness (Figure 70).

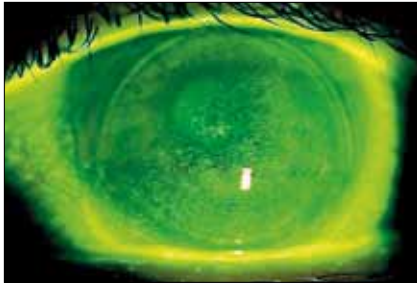


Figure 71. Corneal imprint of bound lens

Corneal indentation

A lens decenters if it has a flat periphery matching a flatter corneal periphery or, on the other hand, a steep periphery preventing lens movement (and occasionally adhering to the cornea).

Lens binding usually occurs with overnight wear of lenses, but may occur with daily wear in the keratoconic patient due the absence of an adequate tear film between the lens and the cornea. The aqueous portion of the tear layer is squeezed out and the mucin layer acts as

an adherent between the lens and the cornea. In these cases, the fit of the lens should be modified and tear supplements should be used throughout the day to encourage lens wetting and movement (Figure 71).

9. Reference List

- Al Mezaine HS, Al Amro SA, Kangave D, et al. Comparison between central corneal thickness measurements by oculus pentacam and ultrasonic pachymetry. *Int Ophthalmol* 2008;28:333–8.
- Aldave AJ, Yellore VS, Salem AK, et al. No VSX1 gene mutations associated with keratoconus. *Invest Ophthalmol Vis Sci* 2006;47:2820–2.
- Ang M, Mehta JS, Arundhati A, Tan DT. Anterior Lamellar Keratoplasty Over Penetrating Keratoplasty for Optical, Therapeutic, and Tectonic Indications: A Case Series. *Am J Ophthalmol* 2008.
- Auffarth GU, Wang L, Volcker HE. Keratoconus evaluation using the Orbscan Topography System. *J Cataract Refract Surg* 2000;26:222–8.
- Bahar I, Kaiserman I, Srinivasan S, et al. Comparison of three different techniques of corneal transplantation for keratoconus. *Am J Ophthalmol* 2008;146:905–12.
- Betts AM, Mitchell LG, Zadnik K. Visual performance and comfort with the Rose K lens for keratoconus. *Optom Vis Sci* 2002;79:493–501.
- Bilgihan K, Ozdek SC, Sari A, Hasanreisoglu B. Microkeratome-assisted lamellar keratoplasty for keratoconus: stromal sandwich. *J Cataract Refract Surg* 2003;29:1267–72.
- Binder PS, Lindstrom RL, Stulting RD, et al. Keratoconus and corneal ectasia after LASIK. *J Cataract Refract Surg* 2005;31:2035–8.
- Brancati F, Valente EM, Sarkozy A, et al. A locus for autosomal dominant keratoconus maps to human chromosome 3p14–q13. *J Med Genet* 2004;41:188–92.
- Brennan NA, Efron N, Carney LG. Critical oxygen requirements to avoid oedema of the central and peripheral cornea. *Acta Ophthalmol (Copenh)* 1987;65:556–64.
- Burger D, Zadnik K. Keratoconus: Contact Lenses for Pre- and Post-Surgery. St. Louis, Missouri. Mosby, 1997;21–52.
- Cheng AC, Rao SK, Lau S, et al. Central corneal thickness measurements by ultrasound, Orbscan II, and Visante OCT after LASIK for myopia. *J Refract Surg* 2008;24:361–5.
- Colin J, Velou S. Current surgical options for keratoconus. *J Cataract Refract Surg* 2003;29:379–86.
- Crews MJ, Driebe WT, Stern GA. The clinical management of keratoconus: a 6 year retrospective study. *CLAO J* 1994;20:194–7.
- Dao CL, Kok JH, Brinkman CJ, van M. Corneal eccentricity as a tool for the diagnosis of keratoconus. *Cornea* 1994;13:339–44.
- de Brabander, Chateau N, Marin G, et al. Simulated optical performance of custom wavefront soft contact lenses for keratoconus. *Optom Vis Sci* 2003;80:637–43.
- DeNaeyer GW, Breece R. Fitting techniques for a scleral lens design. *Contact Lens Spectrum* 2009;34–7.
- Donshik P, et al. The Use of Computerized Videokeratography as an aid in Fitting Rigid Gas Permeable Contact Lenses. *Trans Am Ophthalmol Soc* 1996;XCIV:135–45.
- Dupps WJ, Wilson SE. Biomechanics and wound healing in the cornea. *Exp Eye Res* 2006;83:709–20.
- Edrington TB, Barr JT, Zadnik K, et al. Standardized rigid contact lens fitting protocol for keratoconus. *Optom Vis Sci* 1996;73:369–75.
- Edrington TB, Szczotka LB, Barr JT, et al. Rigid contact lens fitting relationships in keratoconus. Collaborative Longitudinal Evaluation of Keratoconus (CLEK) Study Group. *Optom Vis Sci* 1999;76:692–9.

- Edrington TB, Szczotka LB, Begley CG, et al. Repeatability and agreement of two corneal-curvature assessments in keratoconus: keratometry and the first definite apical clearance lens (FDA CL). CLEK Study Group. Collaborative Longitudinal Evaluation of Keratoconus. *Cornea* 1998;17:267–77.
- Ertan A, Kamburoglu G. INTACS implantation using a femtosecond laser for management of keratoconus: Comparison of 306 cases in different stages. *J Cataract Refract Surg* 2008;34:1521–6.
- Galin M, Berger R. Atopy and Keratoconus. *Am J Ophthalmol* 1958;45:904–6.
- Gasset AR, Lobo L. Dura-T semiflexible lenses for keratoconus. *Ann Ophthalmol* 1975;7:1353–7.
- Gemoules G. A novel method of fitting scleral lenses using high resolution optical coherence tomography. *Eye Contact Lens* 2008;34:80–3.
- Giasson CJ, Perreault N, Brazeau D. Oxygen tension beneath piggyback contact lenses and clinical outcomes of users. *CLAO J* 2001;27:144–50.
- Girard LJ, Soper JW. Indications for contact lenses or keratoplasty in keratoconus. *Ophthalmologica* 1965;150:161–6.
- Gonzalez-Mejome JM, Jorge J, de A, Parafita MA. Soft contact lenses for keratoconus: case report. *Eye Contact Lens* 2006;32:143–7.
- Gundel RE, Libassi DP, Zadnik K, et al. Feasibility of fitting contact lenses with apical clearance in keratoconus. *Optom Vis Sci* 1996;73:729–32.
- Haque S, Jones L, Simpson T. Thickness mapping of the cornea and epithelium using optical coherence tomography. *Optom Vis Sci* 2008;85:E963–E976.
- Haque S, Simpson T, Jones L. Corneal and epithelial thickness in keratoconus: a comparison of ultrasonic pachymetry, Orbiscan II, and optical coherence tomography. *J Refract Surg* 2006;22:486–93.
- Hom MM. Another perspective on keratoconus contact lens fitting. *J Am Optom Assoc* 1986;57:886–8.
- Hood A. Advanced contact lens fitting: part 3 – hospital contact lens practice. *Optician* 1997;214:16–22.
- Hughes AE, Dash DP, Jackson AJ, et al. Familial keratoconus with cataract: linkage to the long arm of chromosome 15 and exclusion of candidate genes. *Invest Ophthalmol Vis Sci* 2003;44:5063–6.
- Hutchings H, Ginisty H, Le G, et al. Identification of a new locus for isolated familial keratoconus at 2p24. *J Med Genet* 2005;42:88–94.
- Kaluzny BJ, Fojt W, Szkulmowska A, et al. Spectral optical coherence tomography in video-rate and 3D imaging of contact lens wear. *Optom Vis Sci* 2007;84:1104–9.
- Kaluzny BJ, Kaluzny JJ, Szkulmowska A, et al. Spectral optical coherence tomography: a new imaging technique in contact lens practice. *Ophthalmic Physiol Opt* 2006;26:127–32.
- Karabatsas CH, Cook SD. Topographic analysis in pellucid marginal corneal degeneration and keratoglobus. *Eye* 1996;10 (Pt 4):451–5.
- Kayazawa F, Nishimura K, Kodama Y, et al. Keratoconus with pellucid marginal corneal degeneration. *Arch Ophthalmol* 1984;102:895–6.
- Kenney MC, Chwa M, Atilano SR, et al. Increased levels of catalase and cathepsin V/L2 but decreased TIMP-1 in keratoconus corneas: evidence that oxidative stress plays a role in this disorder. *Invest Ophthalmol Vis Sci* 2005;46:823–32.
- Kohlhaas M, Spoerl E, Schilde T, et al. Biomechanical evidence of the distribution of cross-links in corneas treated with riboflavin and ultraviolet A light. *J Cataract Refract Surg* 2006;32:279–83.
- Kok JH, van M. Piggyback lenses in keratoconus. *Cornea* 1993;12:60–4.
- Korb DR, Finnemore VM, Herman JP. Apical changes and scarring in keratoconus as related to contact lens fitting techniques. *J Am Optom Assoc* 1982;53:199–205.

- Krachmer JH, Feder RS, Belin MW. Keratoconus and related noninflammatory corneal thinning disorders. *Surv Ophthalmol* 1984;28:293–322.
- Krachmer JH. Eye rubbing can cause keratoconus. *Cornea* 2004;23:539–40.
- Kymionis G, Portaliou D. Corneal crosslinking with riboflavin and UVA for the treatment of keratoconus. *J Cataract Refract Surg* 2007;33:1143–4.
- Kymionis GD, Siganos CS, Tsiklis NS, et al. Long-term follow-up of INTACS in keratoconus. *Am J Ophthalmol* 2007;143:236–44.
- Lawless M, Coster DJ, Phillips AJ, Loane M. Keratoconus: diagnosis and management. *Aust NZ J Ophthalmol* 1989;17:33–60.
- Lee BW, Jurkunas UV, Harissi-Dagher M, et al. Ectatic disorders associated with a claw-shaped pattern on corneal topography. *Am J Ophthalmol* 2007;144:154–6.
- Lee LR, Readshaw G, Hirst LW. Keratoconus: the clinical experience of a Brisbane ophthalmologist. *Ophthalmic Epidemiol* 1996;3:119–25.
- Lee R, Ahmed I. Anterior segment optical coherence tomography: Non-contact high resolution imaging of the anterior chamber. *Techniques in Ophthalmology* 2006;4:120–7.
- Leung KK. RGP fitting philosophies for keratoconus. *Clin Exp Optom* 1999;82:230–5.
- Li X, Rabinowitz YS, Tang YG, et al. Two-stage genome-wide linkage scan in keratoconus sib pair families. *Invest Ophthalmol Vis Sci* 2006;47:3791–5.
- Lim L, Wei RH, Chan WK, Tan DT. Evaluation of keratoconus in Asians: role of Orbscan II and Tomey TMS-2 corneal topography. *Am J Ophthalmol* 2007;143:390–400.
- Lu F, Simpson T, Fonn D, et al. Validity of pachymetric measurements by manipulating the acoustic factor of Orbscan II. *Eye Contact Lens* 2006;32:78–83.
- Mackie IA. Management of keratoconus with hard corneal lenses: The lens lid attachment technique. *Trans Ophthalmol Soc U K* 1977;97:131–5.
- Maguire LJ, Klyce SD, McDonald MB, Kaufman HE. Corneal topography of pellucid marginal degeneration. *Ophthalmology* 1987;94:519–24.
- Mandell RB. Contemporary management of keratoconus. *Int Contact Lens Clin* 1997;24:43–58.
- Mannis MJ, Zadnik K. Contact lens fitting in keratoconus. *CLAO J* 1989;15:282–9.
- Marsack JD, Parker KE, Applegate RA. Performance of wavefront-guided soft lenses in three keratoconus subjects. *Optom Vis Sci* 2008;85:E1172–E1178.
- Matsuda J, Hieda O, Kinoshita S. Comparison of central corneal thickness measurements by Orbscan II and Pentacam after corneal refractive surgery. *Jpn J Ophthalmol* 2008;52:245–9.
- Mazzotta C, Balestrazzi A, Traversi C, et al. Treatment of progressive keratoconus by riboflavin-UVA-induced cross-linking of corneal collagen: ultrastructural analysis by Heidelberg Retinal Tomograph II in vivo confocal microscopy in humans. *Cornea* 2007;26:390–7.
- McMonnies CW. Keratoconus fittings: apical clearance or apical support? *Eye Contact Lens* 2004;30:147–55.
- McMonnies CW. The evidentiary significance of case reports: eye rubbing and keratoconus. *Optom Vis Sci* 2008;85:262–9.
- Moezzi AM, Fonn D, Simpson TL, Sorbara L. Contact lens-induced corneal swelling and surface changes measured with the Orbscan II corneal topographer. *Optom Vis Sci* 2004;81:189–93.
- Nilforoushan MR, Speaker M, Marmor M, et al. Comparative evaluation of refractive surgery candidates with Placido topography, Orbscan II, Pentacam, and wavefront analysis. *J Cataract Refract Surg* 2008;34:623–31.

- Norman C, Caroline PJ. Step-by-step approach to managing keratoconus patients with RGPs. *Contact Lens Forum* 1986;11:25–31.
- O'Donnel C, Codina CM. A hyper-Dk piggyback contact lens system for keratoconus. *Eye Contact Lens* 2004;30:44–8.
- Owen H, Watters GA. An evaluation of the keratoconic cornea using computerised corneal mapping and ultrasonic measurements of corneal thickness. *Ophthalmic Physiol Opt* 1996;16:115–23.
- Ozkurt YB, Sengor T, Kurna S, et al. Rose K contact lens fitting for keratoconus. *Int Ophthalmol* 2007.
- Paik DC, Wen Q, Braunstein RE, et al. Initial Studies Using Aliphatic Nitro Alcohols for Therapeutic Corneal Cross-linking. *Invest Ophthalmol Vis Sci* 2008.
- Parker J, Ko WW, Pavlopoulos G, et al. Videokeratography of keratoconus in monozygotic twins. *J Refract Surg* 1996;12:180–3.
- Paul T, Lim M, Starr CE, et al. Central corneal thickness measured by the Orbscan II system, contact ultrasound pachymetry, and the Artemis 2 system. *J Cataract Refract Surg* 2008;34:1906–12.
- Rabinowitz Y, Dong L, Wistow G. Gene expression profile studies in human keratoconus cornea for NEIBank. *Invest Ophthalmol Vis Sci* 2005;46:1239–46.
- Rabinowitz YS, Garbus JJ, Garbus C, McDonnell PJ. Contact lens selection for keratoconus using a computer-assisted videophotokeratoscope. *CLAO J* 1991;17:88–93.
- Rabinowitz YS, Rasheed K, Yang H, Elashoff J. Accuracy of ultrasonic pachymetry and videokeratography in detecting keratoconus. *J Cataract Refract Surg* 1998;24:196–201.
- Rabinowitz YS. Keratoconus. *Surv Ophthalmol* 1998;42:297–319.
- Raiskup-Wolf F, Spoerl E. Reply: Long-term results of collagen crosslinking with riboflavin and UVA in keratoconus. *J Cataract Refract Surg* 2008;34:1617.
- Randleman JB, Woodward M, Lynn MJ, Stulting RD. Risk assessment for ectasia after corneal refractive surgery. *Ophthalmology* 2008;115:37–50.
- Rao SN, Raviv T, Majmudar PA, Epstein RJ. Role of Orbscan II in screening keratoconus suspects before refractive corneal surgery. *Ophthalmology* 2002;109:1642–6.
- Rose P. Improving a keratoconus lens design. *Contact Lens Spectrum* 2005;20:38–42.
- Shapiro MB, France TD. The ocular features of Down's syndrome. *Am J Ophthalmol* 1985;99:659–63.
- Shovlin JP. Primary Eyecare: Contact lens “fits” over problem eyes. Vol. 3. 1984;67–9.
- Sindt CW. Basic scleral lens fitting and design. *Contact Lens Spectrum* 2008;23:32–6.
- Sonmez B, Doan MP, Hamilton DR. Identification of scanning slit-beam topographic parameters important in distinguishing normal from keratoconic corneal morphologic features. *Am J Ophthalmol* 2007;143:401–8.
- Sorbara L, Chong T, Fonn D. Visual acuity, lens flexure, and residual astigmatism of keratoconic eyes as a function of back optic zone radius of rigid lenses. *Cont Lens Anterior Eye* 2000;23:48–52.
- Sorbara L, Fonn D, Holden BA, Wong R. Centrally fitted versus upper lid-attached rigid gas permeable lenses: part I. design parameters affecting vertical decentration. *Int Cont Lens Clin* 1996;23:99–104.
- Sorbara L, Fonn D, Holden BA, Wong R. Centrally fitted versus upper lid-attached rigid gas permeable lenses: part II. a comparison of the clinical performance. *Int Cont Lens Clin* 1996;23:121–7.
- Sorbara L, Luong J. Contact lens fitting guidelines for the keratoconic patient using videokeratographic data. *Practical Optometry* 1999;10:238–43.
- Sridhar MS, Mahesh S, Bansal AK, et al. Pellucid marginal corneal degeneration. *Ophthalmology* 2004;111:1102–7.
- Steele C. Contact lens fitting today – fitting for the irregular cornea. *Optometry Today(UK)* 2005;45:32–9.

- Szczotka LB, Thomas J. Comparison of axial and instantaneous videokeratographic data in keratoconus and utility in contact lens curvature prediction. *CLAO J* 1998;24:22–8.
- Tabbara KE, Kotb AA. Risk factors for corneal ectasia after LASIK. *Ophthalmology* 2006;113:1618–22.
- Tan BU, Purcell TL, Torres LE, Schanzlin DJ. New surgical approaches to the management of keratoconus and post-LASIK ectasia. *Trans Am Ophthalmol Soc* 2006;104:212–20.
- Tang M, Shekhar R, Miranda D, Huang D. Characteristics of keratoconus and pellucid marginal degeneration in mean curvature maps. *Am J Ophthalmol* 2005;140:993–1001.
- Teng C. Electron microscope study of the pathology of Keratoconus: Part 1. *Am J Ophthalmol* 1963;55:18–47.
- Trimarchi F, Poppi E, Klersy C. [Deep lamellar keratoplasty]. *J Fr Ophthalmol* 2002;25:718–21.
- Tsubota K, Mashima Y, Murata H, Yamada M. A piggyback contact lens for the correction of irregular astigmatism in keratoconus. *Ophthalmology* 1994;101:134–9.
- Tynnismaa H, Sistonen P, Tuupanen S, et al. A locus for autosomal dominant keratoconus: linkage to 16q22.3–q23.1 in Finnish families. *Invest Ophthalmol Vis Sci* 2002;43:3160–4.
- Visser ES, Visser R, van Lier HJJ, Otten HM. Modern scleral lenses, Part I: Clinical features. *Eye Contact Lens* 2007;33:13–20.
- Visser ES. Advanced contact lens fitting: part 5 – the scleral contact lens – clinical indications. *Optician* 1997;214:15–20.
- Wang Y, Rabinowitz YS, Rotter JJ, Yang H. Genetic epidemiological study of keratoconus: evidence for major gene determination. *Am J Med Genet* 2000;93:403–9.
- Ward MA, Artunduaga G, Thompson KP, et al. Phototherapeutic keratectomy for the treatment of nodular subepithelial corneal scars in patients with keratoconus who are contact lens intolerant. *CLAO J* 1995;21:130–2.
- Wasserman D, Itzkowitz J, Kamenar T, Asbell P. Corneal topographic data: its use in fitting aspheric contact lenses. *CLAO J* 1992;18:83–5.
- Wei RH, Lim L, Chan WK, Tan DT. Evaluation of Orbscan II corneal topography in individuals with myopia. *Ophthalmology* 2006;113:177–83.
- Winkler T. Corneo-scleral rigid gas permeable contact lens prescribed following penetrating keratoplasty. *Int Cont Lens Clin* 1998;25:86–8.
- Wollensak G, Sporn E, Reber F, et al. Corneal endothelial cytotoxicity of riboflavin/UVA treatment in vitro. *Ophthalmic Res* 2003;35:324–8.
- Wollensak G. Crosslinking treatment of progressive keratoconus: new hope. *Curr Opin Ophthalmol* 2006;17:356–60.
- Woodward E. The role of rigid contact lenses in the management of keratoconus. *J Brit Contact Lens Assoc* 1991;14:211–7.
- Zadnik K, Barr JT, Edrington TB, et al. Baseline findings in the Collaborative Longitudinal Evaluation of Keratoconus (CLEK) Study. *Invest Ophthalmol Vis Sci* 1998;39:2537–46.
- Zadnik K, Barr JT, Steger-May K, et al. Comparison of flat and steep rigid contact lens fitting methods in keratoconus. *Optom Vis Sci* 2005;82:1014–21.
- Zadnik K, Mutti DO. Contact lens fitting relation and visual acuity in keratoconus. *Am J Optom Physiol Opt* 1987;64:698–702.
- Zadnik K. Meet the challenge of fitting the irregular cornea. *Rev Optom* 1994;131:77–83.

Appendix A

Etiology and Genetics

The exact relationship between cause and effect is still unknown. Many factors have been associated with keratoconus including:

- eye rubbing
- contact lens wear
- allergy and/or atopic disease
- Down syndrome
- connective tissue disorders
- familiarity

Rabinowitz (1998) found that the majority of keratoconic patients were eye-rubbers: 80% compared to 58% reported in the normal population. The same study reported that 44% of the keratoconic population and 36% of the normal population have allergies. Similarly, 15% of the keratoconic and 12% of the normal populations had problems with joint mobility. Ten percent of the keratoconic population had a family history (one or more members) of keratoconus, compared to 0.5% in the normal population.

Nine different chromosomes have been reported to be associated with keratoconus, and many variables indicate that the cause may be genetic, including:

- bilaterality (96% of cases)
- corneal topographic patterns (viewed with videokeratoscopy)
- family history (10 to 23% reported)
- familial aggregation
- twin studies—concordance in monozygotic twins would equal genetic
- segregation analysis (ratio = fraction of individuals in a sibling group that on average will express the disease)
- gene linkage and expression studies

The Lysyl oxidase (LOX) gene plays a role in collagen cross-linking, and when mutated may play a role in keratoconus. A gene expression study has led to the discovery of Aquaporin 5 (a water transport gene having a role in wound healing) suppression in the epithelium of the cornea of the keratoconic patient. This was the first molecular defect ever identified in keratoconus.

On the other hand, some studies that indicate that environmental factors may be responsible for the development of this disease.

Kenney et al. (*IOVS* 2005) demonstrated that oxidative stress on the cornea resulted in corneal thinning, in this disease. This stress leads to an increase in apoptosis and mechanical instability. Activation of degradative enzymes also leads to abnormal regulation of healing resulting in excessive inflammation and stromal haze. There is further evidence of this pathway in studies of post-LASIK ectasia by Dupps, Randleman, Binder and Rabinowitz and Tabbara, where the surgery itself was the source of the oxidative stress on the cornea, causing accumulation of abnormal anti-oxidant enzymes such as super-oxide, peroxide and nitric oxide, leading to abnormal cell function and corneal thinning.

There is also controversy about whether the etiology of keratoconus is found in a defect in the epithelial (ectodermal) or stromal (mesenchymal or collagen) layer of the cornea. Whether the defect is located in the basal epithelium first followed by stromal defects, or vice versa, it appears that eventually both layers are affected.

It is more likely that multiple genes contribute to keratoconus, all of which are related in a common final pathway and trigger the disease when they combine with other mechanical factors.

Appendix B

Surgical Correction of Keratoconus

Penetrating keratoplasty (full thickness)

This is the most frequently performed surgery for 26% of patients with keratoconus. It is 80 to 90% successful. The technique involves removing an 8mm button (all layers of the cornea) from the host and an 8.25mm button from the donor. The surgery is performed using a double running suturing technique, including four to eight interrupted sutures (Figure 1). After a period of six weeks to six months the patient is fit with contact lenses to correct the regular astigmatism that is normally induced with this technique. The rejection rate of the graft is 18% due mostly to neovascularization of the host cornea prior to surgery (Figure 2).

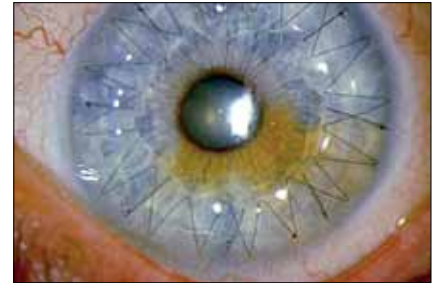


Figure 1. PKP with sutures

Lamellar keratoplasty (partial thickness)

Deep lamellar keratoplasty

This is a technique whereby more than 90% of the host corneal epithelium and stroma is removed (lamellar dissection) and replaced by a full thickness donor cornea with Descemet's membrane removed. This surgery results in no endothelial cell loss, and therefore no endothelial rejection. It also maintains structural integrity, reduces astigmatism and allows for early suture removal. Unfortunately, the much thicker cornea causes a posterior bulge and interface haze, which results in reduced best corrected acuity.

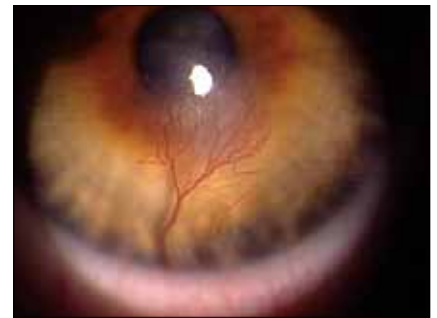


Figure 2. Neovascularization and keratoconus

Disparate thickness lamellar keratoplasty

The objective of this surgery is to restore normal corneal thickness. The host cornea is reduced to 200 microns and the donor to 400 microns, and then the same procedure as in the deep lamellar keratoplasty is performed. Outcomes are better so far than with the deep lamellar technique in case series that have been published and the authors feel that this technique may be a reasonable alternative to penetrating keratoplasty in some cases (Tan et al, 2006).

Intra-lamellar keratoplasty

A microkeratome is used to cut a 9mm flap on the host cornea, and a section of the donor cornea is also cut with a 7.0 to 7.5mm trephine. The donor button is sutured onto the host stromal bed. This surgery has been described as an intra-lamellar tissue insert. After six months, PRK or LASIK is performed to correct the residual astigmatism.

Another method involves the creation of a 10mm lamellar pocket, using an Intralase® Laser in the host cornea. A 9mm 200- to 300-micron donor button is inserted into the stromal pocket. Unfortunately, this procedure results in debris in the interface, mild edema and an increase in corneal thickness of 100 to 200 microns.

INTACS®

INTACS® inserts are 150-degree, precision lathe-cut arcs of polymethylmethacrylate (PMMA) (Figure 3). An Intralase® Laser is used to create channels into which the INTACS® are inserted. The inferior arc is thicker (0.45mm in diameter and 8.1mm radius), creating a “lift”, and the superior arc is thinner (0.25mm in diameter and 6.8mm radius), causing corneal flattening.

INTACS® are more successful:

- with early to moderate cones that are inferiorly displaced (as with pellucid marginal degeneration (PMD))
- if the keratometry readings are <54.00D (6.25mm), with a spherical equivalent of <-5.00D
- if the incision is placed in the steepest refractive meridian
- if there is minimal scarring over the visual axis

They are removable and exchangeable, the procedure is less invasive and the anticipated amount of corneal flattening may improve uncorrected vision. The disadvantage is that if left *in situ* the residual corneal distortion and/or uncorrected refractive error make contact lens fitting more difficult.

Cross-linking agents

A technique that involves the cross-linking of corneal collagen with 0.1% riboflavin phosphate and 20% dextran T 500 solution is now available as a treatment option for progressive keratoconus. The technique claims to increase the rigidity or mechanical strength of the corneal stromal collagen through the photo-polymerization of stromal fibers using a photosensitizing substance (C3-R®) and UV-A light. The treatment is used with low to moderate keratoconic patients (minimum of 400 micron center thickness) on a day surgery basis with the use of topical anesthesia, and takes approximately one hour to perform.

The corneal epithelium is removed in a 9mm diameter zone, and the riboflavin solution is instilled five minutes prior to UV-A irradiation and for every five minutes thereafter up to 30 minutes. The cornea (a 7mm zone) is then exposed to UV-A light for 30 minutes. After the treatment, antibiotics are applied and a bandage contact lens is fit to protect the corneal surface until complete healing of the epithelium takes place.

Although this is a permanent treatment, it has been noted that the strengthening effect can regress and re-treatment may be necessary. The majority of studies have been performed on pig or rabbit eyes, and they conclude that the cross-linking effect is not distributed homogeneously over the corneal depth and that the stiffening effect is concentrated in the anterior 200 to 300 microns of the cornea due to the high absorption of the UV light in those anterior layers. Long-term results on human eyes show some promise, though: Of the 50 to 60% treated subjects who had an increase in best-corrected vision by more than one line, only 20 to 29% maintained that level of vision over a three-year period. Using the confocal microscope, it has been shown that it takes three to six months for the induced stromal edema to clear and for the stromal keratocytes to repopulate. The deep corneal stroma beyond 350 microns appears unaffected by the treatment and endothelial density and morphology were unchanged. Animal corneas that were less than 400 microns in thickness showed endothelial cytotoxicity with the combined UV-A and cross-linking agent, which indicated that thin corneas would not benefit from this procedure.

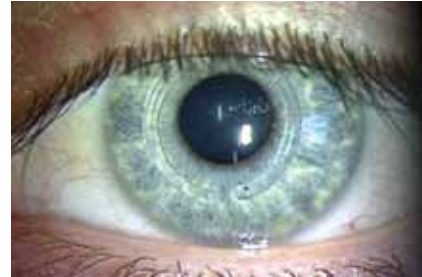

Figure 3. INTACS, white light

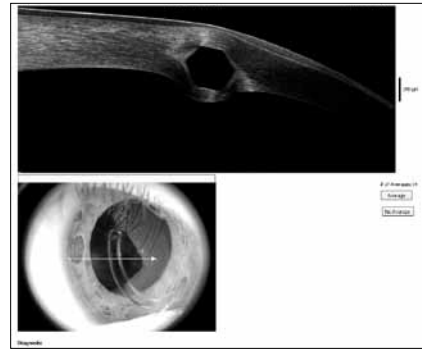


Figure 4. RTVue image of a cross-section of an INTACS

Appendix C

Detection of Keratoconus with the Use of the Orbscan II

The Orbscan II is an instrument that uses scanning-slit photographic techniques to detect the anterior and posterior corneal surfaces with mathematical processes involving triangulation of light. It chooses a sphere of a particular radius that best fits the corneal surface in the mid-periphery (zero elevation) and relates the corneal elevation as lying either above or below the best fit sphere (BFS) in microns or millimeters (Figure 1). Relative to the BFS, these elevation maps are interpreted using the following indices and others that have been reported to categorize whether the corneal features are within the normal range or not:

- Thinnest pachymetry point <470 microns
- Difference in central 7mm pachymetry and minimum point >100 microns
- Thinnest pachymetry point outside 2.5mm radius from the map center
- Maximum (within central 7mm) mean keratometric power >45.50D (7.42mm)
- Broken/irregular/asymmetric bowtie on anterior tangential map
- Difference in anterior axial power in central 3 mm zone >3.00D
- Posterior best fit sphere (BFS) radius $\geq 55.00D$ 6.14mm
- Central 5mm maximum posterior elevation >50 microns
- Bent/warped asymmetry on anterior elevation and posterior elevation maps
- Maximum anterior elevation location corresponds (+/-1mm) to maximum posterior elevation location or maximum anterior tangential radius location or minimum pachymetric point location
- Inferior/temporal location of high point anterior elevation and posterior elevation
- Ratio of anterior BFS radius (mm) to posterior BFS radius (mm) >1.2

Studies have shown that the best indicator of incipient keratoconus is a posterior elevation of the central cornea greater than 40 to 50 microns.

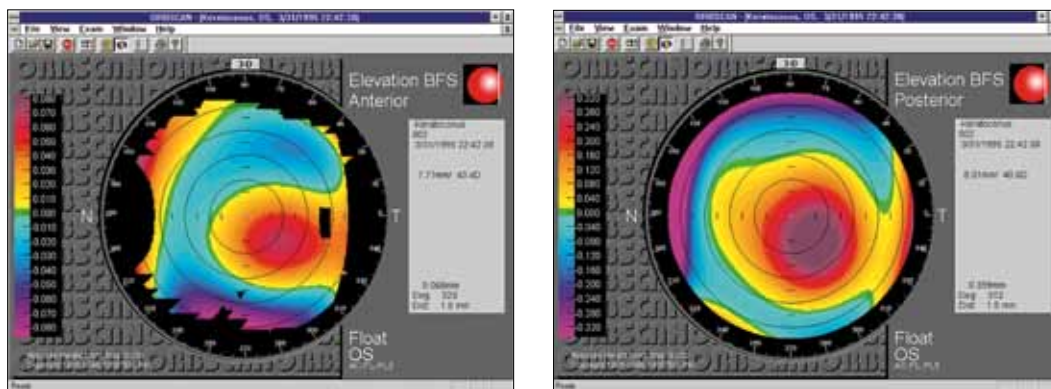

Figure 1. Orbscan II elevation map with best fit sphere (BFS)

Appendix D

Fitting Semi- and Mini-Scleral Lenses

Large diameter lenses, such as 14.5 to 18.2mm, are best fit using the measurement of corneal sag. The Visante OCT uses spectral domain tomography to image the anterior segment of the eye allowing the clinician to use the measurement calipers provided by the software to manually measure the corneal sagittal depth at any chord length. Newer modifications to current corneal topographers have also the ability to measure corneal sag. This measurement aids in the selection of the initial trial lens for especially the advanced keratoconic patient (or post-surgical patient). The MSD lens identifies its lenses with a sag measurement facilitating the matching of the trial lens with the corneal sag. With other lenses where the sag is not given, the sagittal depth may be calculated manually given the lens diameter, e-value and central radius (formulae previously provided) or a fitting nomogram based on the central K readings or corneal astigmatism will be provided. When assessing the fitting of these lenses remember to insert the fluorescein into the bowl of the lens that is filled with either saline or non-preserved re-wetting drops, prior to lens insertion.

Central sagittal depth fitting

When the sagittal depth of the contact lens is less than that of the cornea, the lens will have a flat fitting relationship (Figure 1). Excessively flat fitting lenses with high peripheral clearance over the limbal-scleral junction will result in the appearance of bubbles in that area as seen in Figure 2. A sagittal depth that is excessively larger than that of the cornea will appear to have excessive corneal clearance and usually a large bubble will appear centrally, as in Figure 3. Reducing the sagittal depth of the contact lens will relieve the bubble that was present centrally. A match of the corneal sag and the lens sag will result in an alignment to a slightly steep fitting lens on the cornea (Figure 4).

Mid-peripheral or limbal zone fitting

There should be clearance over the mid-periphery of the lens that is the area of the lens that over lays the limbal area as seen with fluorescein. Any impingement of the lens in this area will cause abrasions and discomfort and on the other hand, excessive clearance

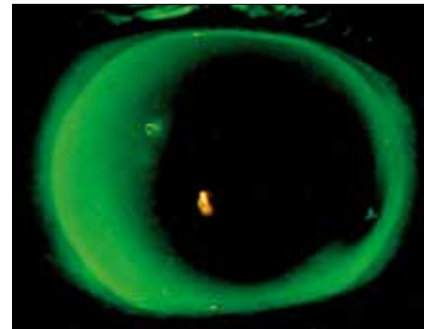


Figure 1. Flat lens

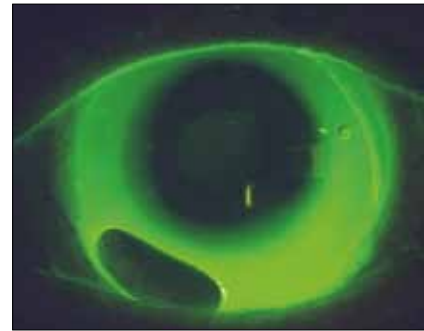


Figure 2. Flat lens with peripheral bubble

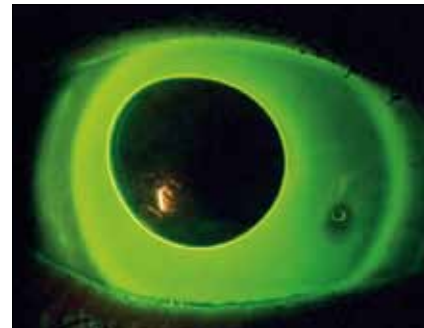

Figure 3. Steep lens with central bubble

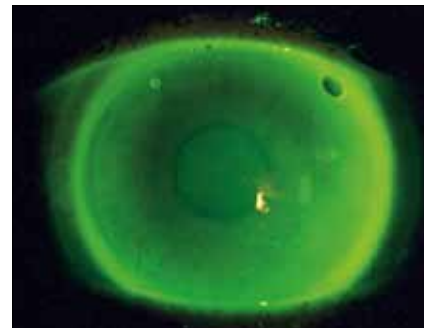


Figure 4. Ideal fit

will result in bubbles where corneal drying may occur. The mid-periphery of the lens may be flattened (when there is excessive touch) or steepened (when there are bubbles) as the case may be. Also, the diameter of the lens may be increased (when there is excessive touch) or reduced (when there are bubbles) when more than one diameter is available.

Scleral fitting zone

The scleral zone of the lens should align over the conjunctiva without impinging or having excessive clearance to maximize comfort and ease of lens removal (even with the use of a contact lens removal device, e.g. DMV). When the scleral zone is too steep and impinging on the conjunctiva, the conjunctival blood vessels will blanch at the edge of the lens/conjunctiva junction. There may be swelling between the limbus and the lens edge that may be evident after lens removal to indicate this finding. Flatter peripheries are needed in this case, but watch that the periphery is not excessively flat. An excessively flat periphery will cause discomfort and possibly lens displacement and thus should be avoided.

Appendix E

Fitting Examples

Fitting example: centered or nipple cone (early stage)

Patient SP, age 17, came in complaining of poor vision, especially at night, despite a recent change in glasses prescription. This patient has a history of allergies and uses eye drops occasionally for dry eye symptoms. History (ocular, personal and family) was negative, and he was not taking any other medications.

Ocular findings

HVID: 11mm, PA = 10mm, PS (pupil size in photopic conditions) = 1.78mm

Tear break-up time (TBUT): 9 sec. (OU)

Retinoscopy: Irregular retinoscopy (scissors) reflex with difficult endpoint determination due to non-orthogonal or irregular astigmatism and change of axis from with-the-rule to oblique and power of astigmatism noted from last visit.

Visual acuities: Corrected to 6/7.5⁻²

Biomicroscopy: Cornea, conjunctiva, lids and lashes:

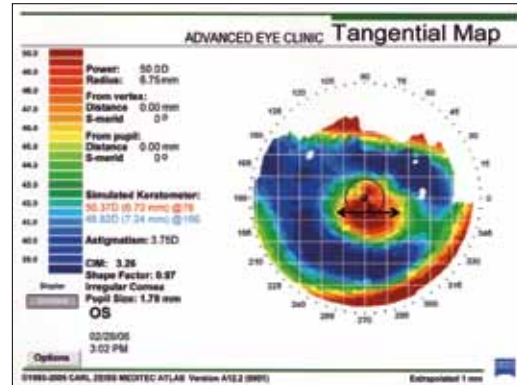


Figure 1: Corneal topography

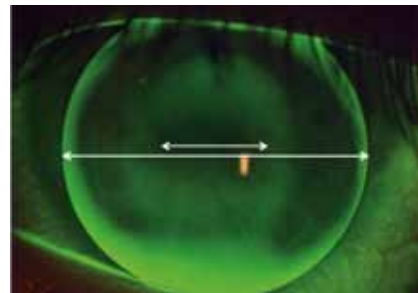


Figure 2: Fluorescein pattern

Sign	Present	Absent
Munson's sign		■
Fleisher's ring	■	
Vogt's striae		■
Subepithelial fibrillary lines	■	
Prominent corneal nerves	■	
Corneal scarring		■
Corneal thinning	■	
Neovascularization		■
Conjunctival hyperemia	■	
Corneal staining, central		■
Corneal staining, peripheral		■
Blepharitis	■	
Meibomian gland dysfunction	■	

Corneal topography:

Simulated K readings (D, mm)	46.62 (7.24) @166 / 50.37 (6.7) @076
Corneal astigmatism (D)	-3.75 x 166
Average K reading (D, mm)	48.50 (6.96)
Steepest K reading (D)	50.00
Steepest cone diameter (mm)	2
Overall cone diameter (mm)	4.5
Q, e and p values*	0.97, 0.98, 0.03

*Q (asphericity) = e², e = eccentricity, p (shape factor) = 1-Q

Fitting Steps

Step 1: Back optic zone/total diameter determination (BOZD/LD)

This patient has an early stage centered or nipple type cone. As this cone progresses (steepens), the cone diameter will become smaller. Trial lenses that come with a floating type of BOZD will suit this patient, since the BOZDs are small and relate to the BOZR, though any trial lens with smaller BOZDs can be fit. Matching the BOZD with the cone diameter will result in a better match between corneal sag and lens sag over the chord of the optic zone.

Cone type	Cone diameters	BOZD ranges	LD ranges
Centered cone: mild	4.0 to 5.0mm	7.4 to 8.1mm	9.4 to 9.6mm

The following lens was chosen to trial fit (See Table 2, page 13).

Cone type	Cone diameters	BOZD ranges	LD ranges
Centered cone: mild	4.0mm	5.5mm	9.4mm

Step 2: Determining back optic zone radius (BOZR)

The back optic zone radius is determined by considering two parameters: first, the amount of corneal astigmatism (Table A) and second, the size of the BOZD (Table B).

To convert millimeters (mm) to diopters (D), use the following formula: $\frac{337.5}{\text{mm or } D} = D \text{ or mm}$
 (See Appendix F: Keratometer Reading Conversion Chart)

Table A: Corneal astigmatism

ΔK (D)	BOZR (D) (9.4LD)
-0.25D to -3.75D	Flat K (D) - 0.609 x (ΔK)
-4.00D to -7.50D	Flat K (D) - 0.491 x (ΔK)*
-7.75D to -16.75D	Flat K (D) - 0.354 x (ΔK)

*Average K for 7.4mm BOZD

Table B: Size of BOZD

Floating BOZD	BOZR (mm)
3.0–3.7mm	Average K (mm) – 0.4mm
3.8–4.9mm	Average K (mm) – 0.35mm
5.0–6.1mm	Average K (mm) – 0.3mm
6.2–7.3mm	Average K (mm) – 0.2mm
7.4–8.0mm	Average K (mm)
>8.1 BOZD	Average K (mm) + 0.2mm

For this lens design and a 9.4 TD with a 7.4 BOZD, and with a spherical central portion of the lens, the initial BOZR would be calculated to be:

ΔK (D)	BOZR (D) (9.4LD/7.4 BOZD)
-3.75D	Average K = 48.50D (6.96mm)

Step 3: Selecting a trial lens

See Table 2, page 13 for an example of trial lens parameters where the back optic zone diameter (BOZD) varies not only with the lens diameter (LD), but with the back optic zone radius (BOZR). As the BOZR steepens, the BOZD decreases in size. The selected lens has a smaller BOZD (5.5 instead of 7.4) and therefore the BOZR needs to be adjusted $(6.96 - 0.3\text{mm}) = 6.66\text{mm}$. Refer to Table B.

BOZR	BOZD	Peripheral AEL	Power
6.66	5.50	“Standard”	-6.00D

Step 4: Assessing lens fit

The lens fit is assessed for centration and movement with the blink. The fluorescein pattern is then assessed using both a cobalt and Wratten #12 yellow enhancing filter. See the flow chart, page 27.

In this case, the central fit was acceptable, but the peripheral fit was too steep. This was due to the high eccentricity value of this cornea and the AEL of the lens did not offer enough axial edge clearance on the eye.

	Initial	Adjusted
BOZR	6.66	No change
BOZD	5.50	No change
TD	9.40	No change
Periphery (AEL)	“Standard”	Flat #2

Step 5: Over-refraction/power determination

Perform an over-refraction over the trial contact lens to predict the contact lens power. The use of an autorefractor may prove to be helpful in these cases, since there is usually a small amount

of residual astigmatism that is difficult to determine with the use of your retinoscope. The autorefractor will provide a fairly good starting point for your subjective over-refraction. The best sphere is determined and is vertexed back to the cornea if $>-4.00D$ and added to the contact lens power. Toric designs are not used to correct residual astigmatism due to its irregularity. High contrast acuities are measured.

CL Power	-6.00D
Over-refraction (sphero-cyl) (autorefraction)	-4.00/-1.25 x 152
Best sphere	-5.00
Vertexed best sphere/acuity	-4.75D 6/6 HCVA
Final CL power = CL BVP + V. best sphere	-10.75D

Step 6: Ordering the final lens

The final lens order will include:

Final lens design: rigid gas permeable <input type="checkbox"/> spherical <input type="checkbox"/> aspheric <input type="checkbox"/> multicurve								
Lab:				Lens name:				
	BOZR	SCR/W	PCR/W	Diameter	BOZD	Power	CT	Color
R								
L	6.66	Flat #2	Flat #2	9.4	5.5	-10.75	0.14	blue
Additional information: <input type="checkbox"/> lenticulate with a plus carrier _____ blend <input type="checkbox"/> medium _____								
Comments: _____ BOZR will be steepened by 0.1mm to 6.55mm and power will be -11.25D upon verification of the lens to compensate for change in sag caused by the flatter periphery.								

Step 7: Lens delivery and follow-up

Lenses were ordered in a high-Dk material to optimize physiological health and with plasma treatment for comfort. The patient was told to continue with artificial tears while wearing the lenses. When the patient was dispensed with the lenses, fit and visual performance matched those found with the diagnostic lenses. A two-week follow up visit showed excellent results. Keratoconic patients are seen often in the first three months as the fitting and power of the lenses are adjusted. Regular three-month visits are advised to monitor the fit and the physiological response to the lenses and at six-month intervals, corneal topography and pachymetry should be repeated.

Fitting example: oval cone (severe stage)

Patient JS, age 49, came in complaining of poor vision, especially at night and also that in general did not feel that he was able to see as well despite a recent change in glasses prescription. He has a history of allergies and uses eye drops occasionally for dry eye symptoms. History (ocular, personal and family) was negative. He was not taking any other medications.

Ocular findings

HVID: 11.0mm, PA = 10mm, PS (pupil size in photopic conditions) = 3.34mm

Tear break-up time (TBUT): 8 sec. (OU)

Retinoscopy: Irregular retinoscopy (scissors) reflex with difficult endpoint determination due to non-orthogonal or irregular astigmatism and change of axis from with-the-rule to oblique and power of astigmatism noted from last visit.

Visual acuities: corrected to 6/7.5⁻²

Biomicroscopy: Cornea, conjunctiva, lids and lashes:

Sign	Present	Absent
Munson's sign	■	
Fleisher's ring	■	
Vogt's striae	■	
Subepithelial fibrillary lines	■	
Prominent corneal nerves	■	
Corneal scarring		■
Corneal thinning	■	
Neovascularization		■
Conjunctival hyperemia	■	
Corneal staining, central	■	
Corneal staining, peripheral		■
Blepharitis		■
Meibomian gland dysfunction	■	

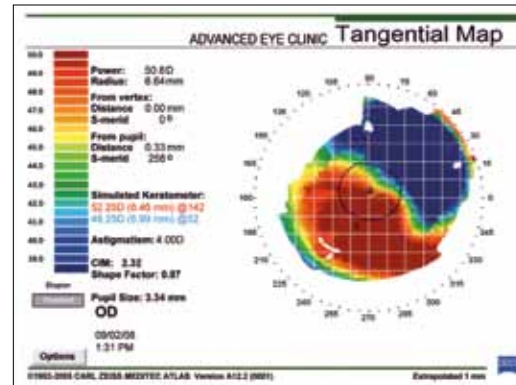


Figure 3: Corneal topography

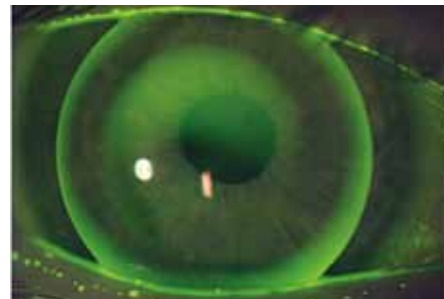


Figure 4: Fluorescein pattern

Corneal topography:

Simulated K readings (D, mm)	48.25 (6.99) @052 / 52.25 (6.46) @142
Corneal astigmatism (D)	-4.00 x 052
Average K reading (D, mm)	50.25 (6.7)
Steepest K reading (D)	54.00
Steepest cone diameter (mm)	5.5
Overall cone diameter (mm)	6
Q, e and p values*	0.87, 0.93, 0.07

*Q (asphericity) = e2, e = eccentricity, p (shape factor) = 1-Q

Fitting Steps

Step 1: Back optic zone diameter/total diameter determination (BOZD/LD)

This patient has advance stage oval-type cone. As this cone progresses (steepens), the cone diameter will become larger. Trial lenses that come with a fixed BOZD will suit this patient since the BOZDs are larger and do not relate to the BOZR, though any trial lens that has larger BOZDs can also be fit. Matching the BOZD with the cone diameter will result in a better match of corneal sag and lens sag over the chord length of the optic zone.

Cone type		Cone diameters	BOZD ranges	LD ranges
Oval	Severe	6.1 to 8.0mm	8.10 to 9.40mm	10.2 to 11.2mm

A multicurve lens with a 10.4mm LD and 8.4mm BOZD was chosen to trial fit.

Step 2: Determining back optic zone radius (BOZR)

The back optic zone radius is determined by considering two parameters: first, the amount of corneal astigmatism (Table C) and second, the size of the BOZD (Table D).

To convert millimeters (mm) to diopters (D), use the following formula: $\frac{337.5}{\text{mm or D}} = \text{D or mm}$
 (See Appendix F: Keratometer Reading Conversion Chart)

Table C: Corneal astigmatism

ΔK (D)	BOZR (D) (9.4LD)
-0.25D to -3.75D	Flat K (D) - 0.609 x (ΔK)
-4.00D to -7.50D	Flat K (D) - 0.491 x (ΔK)*
-7.75D to -16.75D	Flat K (D) - 0.354 x (ΔK)

*Average K with a 7.4 BOZD

Table D: Size of BOZD

Fixed BOZD/LD	BOZR (mm)
5.25–6.5/8.5–8.8mm	Average K (mm) – 0.2mm
7.2–7.5/9.2–9.6mm	Average K (mm)
7.6–8.1/9.8–10.1mm	Average K (mm) + 0.15mm
8.2–8.6/10.2–10.7	Average K (mm) + 0.2 to 0.3mm
8.7–9.4/10.8–11.4	Average K (mm) + 0.4mm

For this lens design, with a spherical central portion of the lens, the initial BOZR would be as follows.

ΔK (D)	BOZR (D) (9.4LD/7.4 BOZD)
-4.00D	Average K = 50.25D (6.7mm)

The chosen lens has a larger BOZD (8.4mm). The final BOZR would be adjusted to:

ΔK (D)	BOZR (D) (9.4LD/7.4 BOZD)	BOZR adjusted
-4.00D	Average K = 50.25D (6.7mm)	Average K + 0.25mm (6.7 + 0.25) = 6.95mm

Step 3: Trial lens selection

10.2–10.6 TD																		
BOZR	7.94	7.76	7.58	7.42	7.18	7.11	7.03	6.96	6.89	6.82	6.75	6.68	6.62	6.55	6.49	6.37	6.25	6.14
BOZD	8.20	8.20	8.20	8.20	8.20	8.20	8.40	8.40	8.40	8.40	8.40	8.40	8.60	8.60	8.60	8.60	8.60	8.60
SC1	8.94	8.76	8.58	8.42	7.98	7.91	7.83	7.76	7.69	7.62	7.55	7.48	7.42	7.50	7.40	7.30	7.25	7.20
SCW1	8.60	8.60	8.60	8.60	8.60	8.60	8.80	8.80	8.80	8.80	8.80	8.80	9.00	9.00	9.00	9.00	9.00	9.00
SC2	10.15	10.10	10.00	9.80	8.98	8.91	8.83	8.76	8.69	8.62	8.55	8.48	8.42	8.55	8.40	8.30	8.25	8.20
SCW2	9.00	9.00	9.00	9.00	9.00	9.00	9.20	9.20	9.20	9.20	9.20	9.20	9.40	9.40	9.40	9.40	9.40	9.40
SC3	11.50	11.40	11.30	11.00	10.18	10.11	10.03	9.96	9.89	9.82	9.75	9.68	9.62	9.65	9.55	9.35	9.35	9.25
SCW3	9.60	9.60	9.60	9.60	9.60	9.60	9.80	9.80	9.80	9.80	9.80	9.80	10.00	10.00	10.00	10.00	10.00	10.00
PC	12.15	12.15	12.10	12.00	11.68	11.61	11.53	11.46	11.39	11.32	11.25	11.18	11.12	11.00	11.00	10.85	10.80	10.75
PCW	10.20	10.20	10.20	10.20	10.20	10.20	10.40	10.40	10.40	10.40	10.40	10.40	10.60	10.60	10.60	10.60	10.60	10.60
AEL	0.245	0.266	0.287	0.303	0.310	0.319	0.349	0.361	0.373	0.386	0.400	0.415	0.457	0.486	0.501	0.538	0.591	0.644

See the table above for examples of multicurve trial lens parameters demonstrating fixed back optic zone diameters (BOZD) that vary only with the lens diameter (LD) (not the back optic zone radius (BOZR)). As the lens diameter increases, the BOZD also increases. Note the axial lens lifts (AEL) that vary as the cornea steepens and the e-value increases the AEL also increases. The trial lens is:

BOZR	BOZD/LD	Peripheral AEL	Power
6.95	8.4/10.4	0.36	-8.00D

Step 4: Lens fit assessment

The lens fit is assessed for centration and movement with the blink. The fluorescein pattern is then assessed using a cobalt and Wratten #12 yellow enhancing filters.

In this case, the central fit was acceptable but, the peripheral fit was too tight. Due to the high eccentricity value of this cornea, the “standard” AEL of the lens did not offer enough axial edge clearance on the eye. The lens will be ordered with a flatter periphery by increasing the AEL by 0.2mm.

	Initial	Adjusted
BOZR	6.95	No change
BOZD	8.4	No change
TD	10.4	No change
Periphery (AEL)	0.36	0.56

Step 5: Over-refraction/power determination

Perform an over-refraction over the trial contact lens to predict the contact lens power. The use of an autorefractor may prove to be helpful in these cases, since there is usually a small amount of residual astigmatism that is difficult to determine with the use of your retinoscope. The autorefractor will provide a fairly good starting point for your subjective over-refraction. The best sphere is determined and is vertexed back to the cornea if $>-4.00D$ and added to the contact lens power. Toric designs are not used to correct residual astigmatism due to its irregularity. High contrast acuities are measured.

CL Power	-8.00D
Over-refraction (sphero-cyl) (autorefraction)	-6.00/-1.75 x 032
Best sphere	-7.00
Vertexed best sphere/acuity	-6.25D 6/6 HCVA
Final CL power = CL BVP + V. best sphere	-14.25D

Step 6: Final lens order

The final lens order will include:

Final lens design: rigid gas permeable <input type="checkbox"/> spherical <input type="checkbox"/> aspheric <input type="checkbox"/> multicurve										
Lab:					Lens name:					
	BOZR	SCR/W			PCR/W	Diameter	BOZD	Power	CT	Color
R	6.95	8.0/0.2, 9.76/0.2, 10.96/0.3			12.25/0.3	10.4	8.4	-14.25	0.16	blue
L										
Additional information: <input type="checkbox"/> lenticulate with a plus carrier <input type="checkbox"/> blend <input type="checkbox"/> medium <input type="checkbox"/>										
Add dot OD _____										
Comments: _____ AEL = 0.561 _____										

Step 7: Lens delivery and follow-up

Lenses were ordered in a high-Dk material to optimize physiological health and with plasma treatment for comfort. The patient was told to continue with artificial tears while wearing the

lenses. When the patient was dispensed with the lenses, fit and visual performance matched those found with the diagnostic lenses. A two-week follow up visit showed excellent results. Keratoconic patients are seen often in the first three months as the fitting and power of the lenses are adjusted. Regular three-monthly visits are advised to monitor the fit and the physiological response to the lenses and at six month intervals, corneal topography and pachymetry should be repeated.

Appendix F: Keratometer Readings Conversion Chart

To convert millimeters (mm) to diopters (D), use the following formula: $\frac{337.5}{\text{mm or D}} = \text{D or mm}$

mm to D

mm	D	mm	D
4.70	71.81	6.65	50.75
4.75	71.05	6.70	50.37
4.80	70.31	6.75	50.00
4.85	69.59	6.80	49.63
4.90	68.88	6.85	49.27
4.95	68.18	6.90	48.91
4.75	71.05	6.95	48.56
4.80	70.31	7.00	48.21
4.85	69.59	7.05	47.87
4.90	68.88	7.10	47.54
4.95	68.18	7.15	47.20
5.00	67.50	7.20	46.88
5.05	66.83	7.25	46.55
5.10	66.18	7.30	46.23
5.15	65.53	7.35	45.92
5.20	64.90	7.40	45.61
5.25	64.29	7.45	45.30
5.30	63.68	7.50	45.00
5.35	63.08	7.55	44.70
5.40	62.50	7.60	44.41
5.45	61.93	7.65	44.12
5.50	61.36	7.70	43.83
5.55	60.81	7.75	43.55
5.60	60.27	7.80	43.27
5.65	59.73	7.85	42.99
5.70	59.21	7.90	42.72
5.75	58.70	7.95	42.45
5.80	58.19	8.00	42.19
5.85	57.69	8.05	41.93
5.90	57.20	8.10	41.67
5.95	56.72	8.15	41.41
6.00	56.25	8.20	41.16
6.05	55.79	8.25	40.91
6.10	55.33	8.30	40.66
6.15	54.88	8.35	40.42
6.20	54.44	8.40	40.18
6.25	54.00	8.45	39.94
6.30	53.57	8.50	39.71
6.35	53.15	8.55	39.47
6.40	52.73	8.60	39.24
6.45	52.33	8.65	39.02
6.50	51.92	8.70	38.79
6.55	51.53	8.75	38.57
6.60	51.14	8.80	38.35

D to mm

D	mm	D	mm	D	mm
38.00	8.88	49.00	6.89	60.00	5.63
38.25	8.82	49.25	6.85	60.25	5.60
38.50	8.77	49.50	6.82	60.50	5.58
38.75	8.71	49.75	6.78	60.75	5.56
39.00	8.65	50.00	6.75	61.00	5.53
39.25	8.60	50.25	6.72	61.25	5.51
39.50	8.54	50.50	6.68	61.50	5.49
39.75	8.49	50.75	6.65	61.75	5.47
40.00	8.44	51.00	6.62	62.00	5.44
40.25	8.39	51.25	6.59	62.25	5.42
40.50	8.33	51.50	6.55	62.50	5.40
40.75	8.28	51.75	6.52	62.75	5.38
41.00	8.23	52.00	6.49	63.00	5.36
41.25	8.18	52.25	6.46	63.25	5.34
41.50	8.13	52.50	6.43	63.50	5.31
41.75	8.08	52.75	6.40	63.75	5.29
42.00	8.04	53.00	6.37	64.00	5.27
42.25	7.99	53.25	6.34	64.25	5.25
42.50	7.94	53.50	6.31	64.50	5.23
42.75	7.89	53.75	6.28	64.75	5.21
43.00	7.85	54.00	6.25	65.00	5.19
43.25	7.80	54.25	6.22	65.25	5.17
43.50	7.76	54.50	6.19	65.50	5.15
43.75	7.71	54.75	6.16	65.75	5.13
44.00	7.67	55.00	6.14	66.00	5.11
44.25	7.63	55.25	6.11	66.25	5.09
44.50	7.58	55.50	6.08	66.50	5.08
44.75	7.54	55.75	6.05	66.75	5.06
45.00	7.50	56.00	6.03	67.00	5.04
45.25	7.46	56.25	6.00	67.25	5.02
45.50	7.42	56.50	5.97	67.50	5.00
45.75	7.38	56.75	5.95	67.75	4.98
46.00	7.34	57.00	5.92	68.00	4.96
46.25	7.30	57.25	5.90	68.25	4.95
46.50	7.26	57.50	5.87	68.50	4.93
46.75	7.22	57.75	5.84	68.75	4.91
47.00	7.18	58.00	5.82	69.00	4.89
47.25	7.14	58.25	5.79	69.25	4.87
47.50	7.11	58.50	5.77	69.50	4.86
47.75	7.07	58.75	5.74	69.75	4.84
48.00	7.03	59.00	5.72	70.00	4.82
48.25	6.99	59.25	5.70	70.25	4.80
48.50	6.96	59.50	5.67	70.50	4.79
48.75	6.92	59.75	5.65	70.75	4.77

Appendix G: Conversion Chart: Distance Vision Nomenclature

Snellen (ft.)	Snellen (m.)	LogMar	Min. of Arc
20/200	6/60	1.0	0.1
20/160	6/48	0.9	0.125
20/100	6/30	0.8	0.2
20/80	6/24	0.7	0.25
20/70	6/23	0.6	0.28
20/63	6/18	0.5	0.32
20/50	6/15	0.4	0.4
20/40	6/12	0.3	0.5
20/32	6/9	0.2	0.64
20/25	6/7.5	0.1	0.8
20/20	6/6	0.0	1.0



Centre for Contact Lens Research

School of Optometry, University of Waterloo

200 University Avenue West

Waterloo, Ontario, Canada N2L 3G1

519 888-4742

<http://cclr.uwaterloo.ca>